


Umberto Demoner Ramos 
 Flavia Adelino Suaid
 Ulf M. E. Wikesjö
 Cristiano Susin
 Mario Taba Jr.
 Arthur Belém Novaes Jr.

Comparison between two antimicrobial protocols with or without guided bone regeneration in the treatment of peri-implantitis. A histomorphometric study in dogs

Authors' affiliations:

Umberto Demoner Ramos, Flavia Adelino Suaid, Mario Taba Jr., Arthur Belém Novaes Jr. Department of Bucco-Maxillo-Facial Surgery and Traumatology, and Periodontology, School of Dentistry of Ribeirão Preto, University of São Paulo, Ribeirão Preto, SP, Brazil
 Ulf M. E. Wikesjö, Cristiano Susin, Laboratory for Applied Periodontal & Craniofacial Regeneration, Dental College of Georgia, Augusta University, Augusta, GA, USA

Corresponding author:

Umberto Demoner Ramos, PhD
 Rua misael pedreira da silva,
 98 sala 102 Santa Lúcia.
 Vitória-ES, ZIP CODE 23056-230, Brazil
 Tel.: +55 27 997599091
 Fax: +55 27 33253094
 e-mail: umbertodramos@gmail.com

Key words: animal experiments, biomaterials, bone regeneration, bone substitutes, guided tissue regeneration, wound healing

Abstract

Objectives: This study used a dog model to evaluate two antimicrobial protocols with or without guided bone regeneration (GBR) in the surgical reconstruction of peri-implantitis defects.

Material and methods: Eight beagle dogs subject to ligature-induced peri-implantitis were used. The animals either received antimicrobial photodynamic therapy or topical tetracycline hydrochloride combined with GBR or as stand-alone surgical interventions. Block biopsies of the defect sites for histological analysis were obtained at euthanasia, 12 weeks postsurgery. The primary outcome of the study was re-osseointegration; secondary outcomes included alveolar bone gain and remaining defect characteristics. The effects of the implant site, early exposure, and type of antimicrobial protocol on bone regeneration were also evaluated.

Results: No significant differences were observed between the two antimicrobial protocols, and the adjunctive use of GBR failed to significantly improve re-osseointegration or bone gain using either protocol. Buccal sites and implant early exposure negatively affected bone regeneration.

Conclusion: Both antimicrobial therapies stand-alone or combined with GBR allowed similar and limited bone gain.

The dental implant-anchored prosthesis has become a *de facto* alternative for the replacement of missing or terminally failing teeth. Whereas dental implant long-term survival rates approach 95% (Moraschini et al. 2015), biological and mechanical complications account for a significant increase of failing implants. Peri-implantitis, a biological complication, is an inflammatory lesion caused by oral bacteria leading to loss of bone at osseointegrated dental implants (Lang & Berglundh 2011). According to a recent meta-analysis, the overall prevalence of peri-implantitis approximates 22% (Derks & Tomasi 2015), confirmed by the first population-based epidemiologic study on peri-implantitis (Derks et al. 2016; Tenenbaum et al. 2016). Peri-implantitis and chronic periodontitis share several biological and clinical characteristics (Berglundh et al. 2011). However, human peri-implantitis lesions appear larger, deeper, and present with higher counts of neutrophilic granulocytes and osteoclasts

than human periodontitis lesions (Carcuac & Berglundh 2014) also verified in animal models (Carcuac et al. 2013).

Thorough mechanical cleansing of the exposed implant appears a prerequisite for resolution of the peri-implant inflammatory lesion, however, it is insufficient to promote bone regeneration and re-osseointegration, even with the aid of systemic antibiotics (Persson et al. 2001). Several methods including disinfectants, abrasive technologies, and lasers have been proposed to cleanse the exposed implant (Hanisch et al. 1997; Salvi et al. 2007; Romanos et al. 2009; Park 2012; de Waal et al. 2015). In clinical settings, however, access to effectively decontaminate the implant appears seriously limited by the implant macro- and microstructure and the peri-implant bone configuration.

Based on a long tradition of use in periodontics, the adjunct use of antimicrobials, including tetracycline and chlorhexidine, has been studied for the disinfection of the

Date:

Accepted 12 November 2016

To cite this article:

Ramos UD, Suaid FA, Wikesjö UME, Susin C, Taba Jr M, Novaes Jr AB. Comparison between two antimicrobial protocols with or without guided bone regeneration in the treatment of peri-implantitis. A histomorphometric study in dogs.
Clin. Oral Impl. Res. 00, 2017, 1–8
 doi: 10.1111/clr.12998

implant surface with mixed outcomes (Carcuac et al. 2015). Moreover, widespread use of antibiotics has led to antimicrobial resistance, which has become a global public health problem (Levy & Marshall 2004). In perspective, antimicrobial photodynamic therapy (aPDT) has been introduced to potentially overcome some of these limitations. aPDT represents a technology in which the bacterial intra- and extracellular structures are targeted by a photosensitizer that absorbs light energy, usually from a red laser source, and produces singlet oxygen and protein denaturation inside the bacteria leading to bacterial cell death. Others suggest that aPDT may improve healing through the modulation of cytokines and chemokines (Braham et al. 2009). Clinical studies have shown promise following the use of aPDT in periodontal defects (Lulic et al. 2009; Moreira et al. 2015; Ramos et al. 2015). Moreover, red laser has been shown to improve bone healing and osseointegration in animal models (Blay et al. 2015; Mayer et al. 2015) without development of bacterial resistance (Tavares et al. 2010).

Guided bone regeneration (GBR) has been used for dental implant site preparation over more than 30 years (Nyman et al. 1990). Recent clinical studies report the use of various bone biomaterials as stand-alone treatments or embedded in a GBR protocol in the management of the peri-implantitis defects (Roos-Jansaker et al. 2007; Schwarz et al. 2009; Rocuzzo et al. 2011). Bone biomaterials of human or animal origin have become preferred options, a bovine bone mineral (BBM) appearing the most widely studied biomaterial for GBR (Esposito et al. 2014). Nevertheless, to date, no predictable regenerative protocol has emerged in the clinical management of peri-implantitis (Persson et al. 1999; Renvert et al. 2009; Esposito et al. 2012).

Few studies have evaluated aPDT as an adjunctive in the management of peri-implantitis (Dortbudak et al. 2001; Shibli et al. 2003, 2006). Little is known about its effect on decontamination and effect on bone regeneration after infection of the implant surface, in particular bone-implant contact. The aim of this study was to compare two antimicrobial protocols stand-alone or combined with GBR in the surgical reconstruction of peri-implantitis defects using a dog model.

Material and methods

This study followed a protocol approved by the Animal Experimental Ethics Committee,

University of São Paulo, Ribeirão Preto, Brazil (protocol number 06.1.458.53.5). Animal welfare including transport, housing, handling, enrichment, and veterinary care followed the University of São Paulo animal care guidelines. This study, conducted between July 2012 and July 2013, was divided into two phases: (i) ligature-induced peri-implantitis and (ii) surgical reconstruction of induced peri-implantitis defects comparing two antimicrobial protocols in the presence or absence of GBR (Fig. 1). This report was prepared in harmony with the ARRIVE guidelines for reporting animal research (Kilkenny et al. 2010).

Animals

Eight male purpose-bred beagle dogs, 18–24 months old, approximate weight 15 kg, obtained from a licensed vendor (Instituto Royal, São Roque, São Paulo, Brazil) were used. The animals were individually housed in 1.6×5 m runs and had *ad libitum* access to water and standard laboratory dog-food-diet (Royal Canin, Descalvado-SP, Brazil) throughout the study.

Materials

Titanium dental implants (BoneLevel TML SLA, $\varnothing 3.3 \times 10$ mm, Straumann, Basel, Switzerland) and healing abutments ($\varnothing 4.1 \times 3.5$ mm, Straumann, Basel, Switzerland) were used.

BBM (Bio-Oss, Geistlich Pharma, Wolhusen, Switzerland) in combination with a resorbable porcine collagen membrane (Bio-Gide, Geistlich Pharma, Wolhusen, Switzerland) was used for GBR.

For the aPDT, a handheld, battery-operated, diode laser (HELBO mini-laser 2075 F dent, HELBO Photodynamic Systems, Grieskirchen, Austria) was used. The device was set to a wavelength of 660 nm and fluency of 212 mW/cm^2 . The laser was irradiated through an 8.5-cm-long flexible fiber optic tip curved at a 60° angle with a $\varnothing 0.06$ cm spot size. A 10 mg/mL of phenothiazine chloride

solution (HELBO Blue Photosensitizer, HELBO Photodynamic Systems, Grieskirchen, Austria) was used as photosensitizer.

Surgical procedures

Food was withheld the night preceding surgeries. For all surgical events, the animals were pre-anesthetized using 10% zolazepam (0.10 mL/kg IM) and acepromazine (0.2–0.3 mg/kg IM). The animals were then maintained on gas anesthesia (isoflurane 1–2% to effect). Depth of anesthesia was monitored by lack of response to toe pinch, lack of corneal reflex, and by monitoring depth of respiration, respiratory rate, and heart rate; all anesthesia and related procedures were performed and monitored by veterinary staff. Routine dental infiltration anesthesia (mepivacaine 2% norepinephrine 1:100,000) was used at the surgical sites. An opioid (tramadol chlorhydrate; 3 mg/kg BID for 3 days) and a nonsteroidal anti-inflammatory agent (ketoprofen; 1 mg/kg SID) were used for post-surgery pain control.

Extractions and dental implant installation

Flapless bilateral surgical extractions of the mandibular premolar and 1st molar teeth were performed in preparation for dental implant installation. Atraumatic extractions were carried out bisectioning the teeth at the furcation level using a high-speed hand piece and surgical burs, and individual roots were then extracted using elevators and forceps. Interrupted sutures (5.0 Vicryl Ethicon, Johnson & Johnson, São Jose dos Campos, Brazil) were used to provide wound closure for primary intention healing. Sutures were removed at 2 weeks, the extraction sites were allowed to heal for an additional 6 weeks, dental prophylaxis carried out every 4 weeks.

Buccal and lingual mucoperiosteal flaps were raised following a mid-crestal incision to expose the edentulated alveolar ridge for dental implant installation. Four dental implants were placed in each mandibular jaw

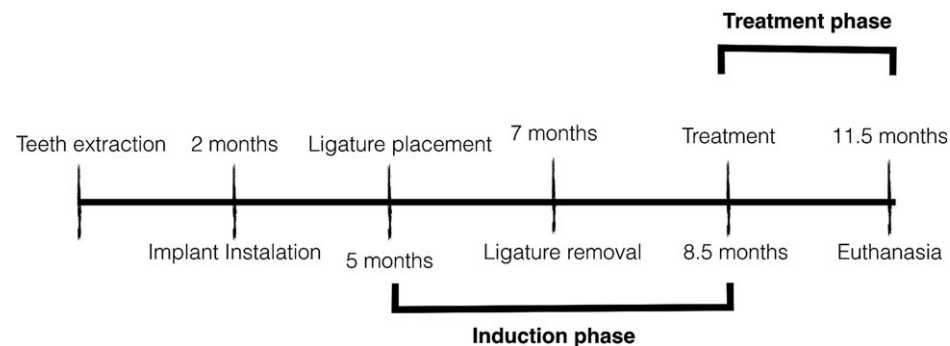


Fig. 1. Study flowchart.

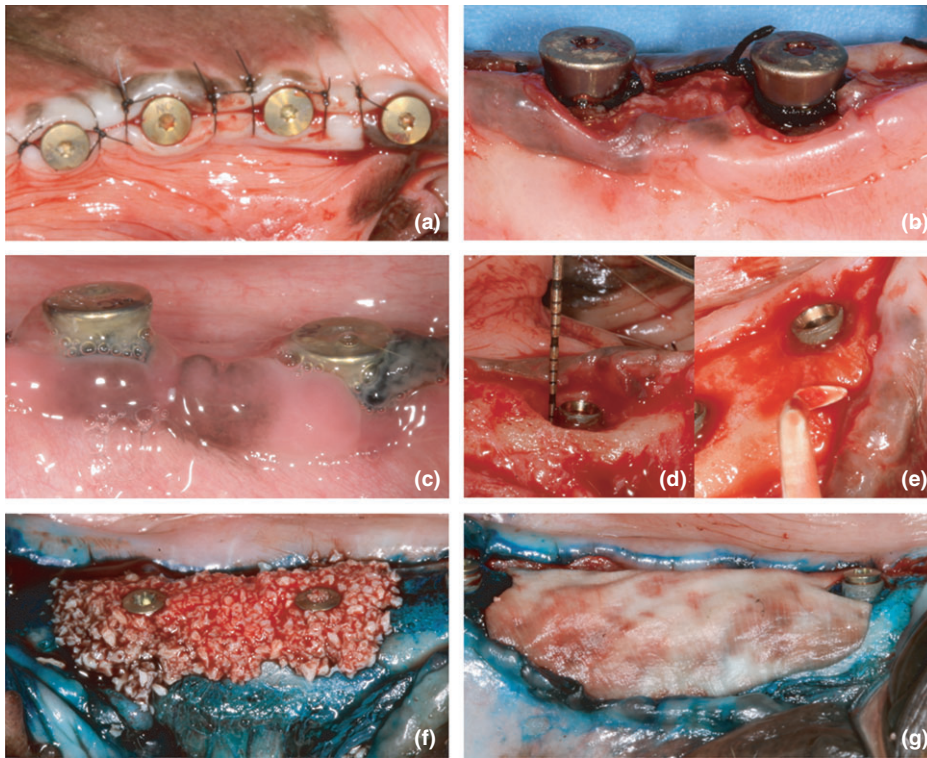


Fig. 2. Dental implant installation (a); surgical placement of silk ligatures (b); tissue conditions at ligature removal (c); defect height assessment (d); implant debridement (e); and placement of BBM level with the cover screw (f) and the collagen membrane for GBR (g).

quadrant following the manufacturer's protocol. Flaps were then approximated and sutured (5-0 Mononylon, Ethicon, São Jose dos Campos, Brazil) for transmucosal wound healing (Fig. 2a). Sutures were removed at 2 weeks, the surgical sites were allowed to heal for an additional 6 weeks, dental prophylaxis carried out every 4 weeks. A broad-spectrum systemic antibiotic (Pentabiotico Veterinário™, Fort Dodge Animal Health, Campinas, São Paulo, Brazil; 0.5 mg/kg SID for 3 days) was used during the 8 weeks following dental implant installation.

Peri-implantitis induction

For peri-implantitis induction, silk ligatures (3-0 Silk Ethicon, Johnson & Johnson, São Jose dos Campos, Brazil) were placed around the healing abutments for 8 weeks. Ligatures were checked weekly, and missing ligatures were immediately replaced. Ligatures were then removed, and peri-implant lesions were allowed to progress undisturbed for an additional 6 weeks (Fig. 2b, c). The standard dog-food-diet was wetted to a slurry during peri-implantitis induction to enhance dental plaque formation. Peri-implantitis progression was monitored using radiographic recordings at 4-week intervals (RVG Trophy, Carestream Dental, Atlanta, GA, USA).

Peri-implantitis defect reconstruction

A mucoperiosteal flap was elevated without releasing incisions for the surgical reconstruction of the peri-implantitis defects. The defects were debrided, and exposed dental implants were instrumented using plastic curettes (Implacare-IMPHDL6, Hu-Friedy, Chicago, IL, USA). An experienced examiner (UDR) assessed peri-implantitis defect dimensions following defect debridement using a manual periodontal probe (PCP15, Hu-Friedy, Chicago, IL, USA; Fig. 2d, e):

- Defect depth: distance from the implant platform to the base of the peri-implantitis defect at four sites per implant.
- Crestal bone level: distance from the implant platform to the level of the alveolar crest at four sites per implant.

Treatment allocation was assigned using computer-generated numbers (Microsoft Excel®, Redmond, WA, USA); each animal received all four treatments, and dental implants were randomly allocated in pairs to one of the following treatments (Fig. 2f, g):

- TTC: Exposed dental implants were conditioned with tetracycline HCL for 3 min using cotton pellets soaked in a 50 mg/mL solution, and cotton pellets were exchanged every 30 sec. The surgical sites were then thoroughly rinsed with sterile saline.

- TTC/GBR: Exposed dental implant was conditioned with tetracycline HCL as described above. The peri-implant defects were then filled to capacity with the particulate BBM, and a collagen membrane was adapted over the BBM. Fixation pins were not used.
- aPDT: Peri-implant defects were filled to capacity with the photosensitizer, and the solution was left in place for 5 min. The surgical sites were then thoroughly rinsed with sterile saline to remove the photosensitizer solution to minimize optical shielding. The exposed dental implants were divided into six areas, and the laser was applied for 30 sec over each area for a total dose of 44 J/cm².
- aPDT/GBR: aPDT and GBR were carried out as described above.

The surgical sites were closed for primary intention healing using interrupted sutures (5-0 Mononylon Ethicon, São Jose dos Campos, Brazil). Sutures were removed at 2 weeks postsurgery. The animals were maintained on the softened dog-food-diet for 2 weeks. Daily topical application of a 0.12% chlorhexidine gluconate solution (Periogard® 0.12%, Colgate Palmolive, São Paulo, Brazil) was used to support plaque control for 2 weeks. Systemic antibiotics were not administered during this phase of study. The animals were euthanized at 12 weeks following reconstructive surgery using a sodium thiopental and potassium chloride overdose administered intravenously following induction of deep anesthesia. Block biopsies including dental implants, alveolar bone, and mucosa were then collected and immediately transferred into a large volume 4% neutral phosphate-buffered formalin.

Histological processing

Formalin-fixed specimens were dehydrated using a standard ascending alcohol concentration and then infiltrated with resin (LR White, London Resin Company, Berkshire, UK). Half of the specimens were sectioned in a mesiodistal and the other half in a buccolingual vertical plane using established techniques (Donath & Breuner 1982). The histological sections were prepared to a final thickness of approximately 40 µm and were stained using toluidine blue and alizarin red.

Histological evaluation

Two experienced examiners (UW and UDR) independently performed the histopathologic evaluation using incandescent and polarized

light microscopy (BX 51, Olympus America, Melville, NY, USA). Observations of peri-implant bone formation and remodeling (formation/resorption), woven and lamellar bone, cortex formation, fibrovascular tissue and marrow, inflammatory response, vascularity, and residual biomaterials (BBM and collagen membrane) were performed. When consensus between the two examiners was not achieved, an independent examiner (CS) reviewed the histological findings to reach a final decision, the examiners masked with regard to the treatment rendered to the extent possible as the presence of BBM is an obvious finding.

Histometric analysis

A calibrated examiner (UDR) performed the histometric analysis using incandescent and polarized light microscopy (BX51, Olympus America, Melville, NY, USA), a microscope digital camera system (DP73, Olympus America, Melville, NY, USA), and a PC-based image analysis system (cellSens® Dimension 1.11 Digital Imaging Software, Olympus America, Melville, NY, USA). The examiner was masked with regard to the treatment rendered to the extent possible as the presence of BBM is an obvious finding.

Intra-examiner reproducibility was evaluated comparing histological measurements made 4 weeks apart. The concordance correlation coefficient according to Lin (2000) was calculated. The concordance correlation coefficients for the histometric assessments were >0.95, indicating a high degree of agreement and small measurement error. The following histological measurements were collected using central sections from each implant:

- Defect depth: distance from the implant platform to the base of the peri-implantitis defect pretreatment (verified by two independent examiners).
- Residual defect: distance from the implant platform to the most coronal bone-implant contact along the implant.
- Crestal bone level: distance from the implant platform to the alveolar crest.
- Total osseointegration: fraction bone-implant contact (BIC) from base of the defect to the implant shoulder.
- Osseointegration within newly formed bone: fraction bone-implant contact (BIC) from the base of the defect to the most coronal bone-implant contact.

Sample size calculation

Based on estimates derived from a previous study using a comparable study design and

implant surface (Shibli et al. 2006), a sample size of eight animals would provide 90% power to detect a mean difference of $20 \pm 15\%$ in re-osseointegration between treatments using a two-sided paired *t*-test and significance level of 0.05.

Statistical analysis

The primary outcome of this study was re-osseointegration; secondary outcomes included alveolar bone gain and remaining defect characteristics. Repeated-measures ANOVA was used to compare treatment groups with regard to defect characteristics and treatment outcomes. Measurements made at the implant level were aggregated at the animal level that the animal was used as the unit of analysis ($n = 8$). Generalized estimating equations were used to model the relationship between treatment outcomes (residual defect depth, new bone gain, new bone BIC) and explanatory variables (TTC/aPDT, GBR, site, location, implant exposure). Measurements at implant level were used, and estimates were adjusted for the clustering of observations into animals ($n = 8$ animals and 55 implants). An exchangeable correlation and robust variance estimator were used. Wald tests were used for multiple comparisons, and the level of significance was set at 5%. Data distribution was evaluated using distribution plots, and no major departures from the normal distribution were observed.

Results

Clinical findings

All animals completed the study. Fifty-five of 64 implants were available for the histological analysis: three implants failed to osseointegrate, five implants were lost during peri-implantitis induction, and one implant was lost in histological processing. The treatment distribution of the 55 implants evaluated histologically was as follows: 28 implants were

sectioned using a buccolingual (TTC: 8; TTC/GBR: 7; aPDT: 6; aPDT/GBR: 7) and 27 implants using a mesiodistal orientation (TTC: 7; TTC/GBR: 6; aPDT: 8; aPDT/GBR: 6). Healing following defect reconstruction was generally uneventful; however, suture-line dehiscences were observed within 1 week in two animals. These sites were wiped clean using sterile gauze and irrigated with a chlorhexidine gluconate solution (Periogard® 0.12%, Colgate Palmolive, São Paulo, Brazil).

No significant differences were observed among experimental protocols with regard to peri-implantitis defect characteristics (Table 1). Mean clinical defect depth ranged from 1.8 ± 0.5 to 2.6 ± 0.9 mm for the various protocols; crestal bone levels ranged from 0.9 ± 0.9 to 1.3 ± 0.9 mm.

Histological analysis

Eleven of the 55 dental implants (20%), equally distributed among experimental protocols aPDT (2), TTC (3), aPDT/GBR (4), and TTC/GBR (2), were deemed exposed. A localized inflammatory reaction was observed at five implants (9%), representing three implants receiving TTC and two implants receiving aPDT/GBR. Twenty-one (75%) of 28 implants receiving GBR exhibited residual BBM representing 13 implants receiving aPDT/GBR and eight implants receiving TTC/GBR. All sites showed BBM encapsulated in mature dense connective tissue without indications of associated bone formation (Fig. 3). None of the sites showed evidence of BBM resorption/biodegradation, that is, scalloped borders and/or the presence of osteoclast-like cells, or BBM erosion. Six sites receiving aPDT/GBR and six sites receiving TTC/GBR exhibited unique BBM particles trapped within newly formed bone (Fig. 4), again without overt signs of associated bone metabolic activity. No BBM particles were found in direct contact with implant surfaces.

Table 1. Pretreatment peri-implantitis defect characteristics, and following antimicrobial tetracycline HCL (TTC) or photodynamic therapy (aPDT) with or without guided bone regeneration (GBR; means \pm SD in mm, $n = 8$ animals)

	TTC	aPDT	TTC/GBR	aPDT/GBR	P-value
Clinical defect characteristics					
Defect depth	1.8 ± 0.5	2.0 ± 0.8	2.1 ± 0.5	2.6 ± 0.9	0.06
Crestal level	0.9 ± 0.9	0.9 ± 0.7	1.3 ± 0.9	1.3 ± 0.9	0.12
Histometric parameters					
Pretreatment defect depth	2.3 ± 0.9	2.3 ± 0.8	2.5 ± 0.5	3.0 ± 1.2	0.13
Residual defect depth	1.3 ± 1.4	1.3 ± 1.0	1.4 ± 1.0	1.8 ± 1.5	0.85
Crestal bone level	0.8 ± 1.2	0.5 ± 0.8	0.8 ± 1.3	0.8 ± 1.6	0.41
Linear bone gain	1.0 ± 0.5	1.0 ± 0.6	1.1 ± 0.5	1.2 ± 0.6	0.56
Bone gain (%)	53.1 ± 36.6	46.9 ± 26.9	49.9 ± 29.0	47.3 ± 28.5	0.89
Total osseointegration (%)	36.2 ± 21.9	35.5 ± 17.2	36.3 ± 21.3	27.6 ± 15.3	0.56
Osseointegration within new bone (%)	61.9 ± 21.5	61.0 ± 22.4	68.5 ± 22.2	59.2 ± 11.8	0.74

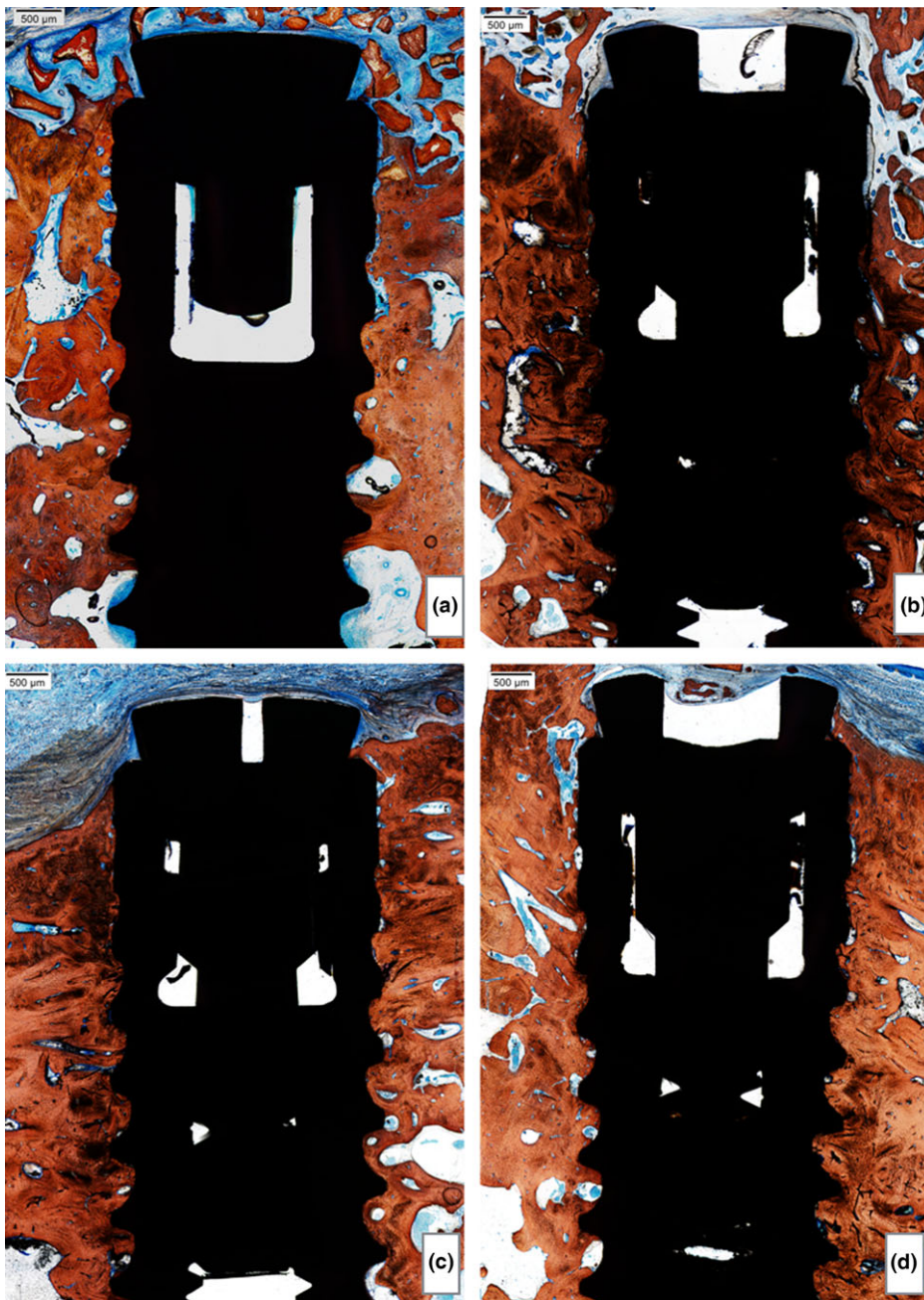


Fig. 3. Representative photomicrographs of mesial/distal sectioned peri-implantitis defects following application of the a) aPDT+GBR; b) TTC+GBR; c) aPDT; d) TTC.

Histometric analysis

Mean pretreatment defect depth ranged from 2.3 ± 0.8 to 3 ± 1.2 mm (Table 1). No significant differences were observed following the experimental protocols with regard to new bone formation and BIC. Total bone gain ranged from 1 ± 0.5 to 1.2 ± 0.6 mm equating 47% and 53% resolution of the peri-implantitis defect, in turn demonstrating limited effects of the antimicrobial protocols on bone formation and no additive effect of the BBM/collagen membrane GBR protocol. BIC within the limited newly formed bone ranged from $59.2 \pm 11.8\%$ to $68.5 \pm 22.2\%$.

Predictors for residual defect depth, peri-implant bone gain, and BIC within newly formed bone are presented in Table 2. No significant effects on treatment outcomes could be observed for TTC or aPDT with or without GBR after adjusting for the other cofactors in the model. Proximal and lingual sites yielded significantly smaller residual defect depth and greater bone gain than buccal sites. Significantly increased bone gain was also observed at posteriorly over anteriorly located implants. Implant exposure had a significant detrimental effect on all parameters evaluated.

Discussion

The aim of the present study was to compare two antimicrobial protocols stand-alone or combined with GBR in the surgical reconstruction of peri-implantitis defects using a dog model. Disinfection of the exposed dental implant was achieved using topical application of TTC or aPDT. GBR comprised application of BBM in combination with a collagen membrane. Resolution of the peri-implantitis defects was incomplete without significant differences among treatments.

Several protocols have been proposed to disinfect the exposed dental implant in the management of peri-implantitis; few studies have assessed the effect of aPDT. Using a peri-implantitis dog model, Shibli et al. (2006) compared surgical debridement with aPDT to resolve peri-implantitis defects at four commercially available implant systems. When combined with an expanded polytetrafluoroethylene (ePTFE) membrane for GBR, implants receiving aPDT yielded enhanced osseointegration compared with those receiving surgical debridement alone. Direct comparisons with the present study should, however, be made with caution. Whereas both studies used aPDT, they were performed using different pre-irradiation intervals, photosensitizer concentration, and laser parameters, preventing meaningful comparisons (Shibli et al. 2003, 2006). In perspective, increasing sensitizer concentration and total light dose/fluency increases the photodynamic activity (Qin et al. 2008a). The present study used a 5-min pre-irradiation interval, which has been shown to optimally target pathogenic bacteria (Qin et al. 2008a, 2008b). The use of multiple applications of aPDT for periodontal treatment has been shown to yield improved outcomes compared with single applications (Lulic et al. 2009; Moreira et al. 2015; Ramos et al. 2015). However, when combined with surgery as in the present study, an extended irradiation interval was used to compensate for the surgical protocol that precluded repeated applications.

In the present study, no significant differences were observed with the use of TTC or aPDT combined with GBR including BBM and a collagen membrane compared with TTC or aPDT stand-alone; linear bone fill ranged from 1 to 1.2 mm, yielding approximately 50% defect closure. Schwarz et al. (2011) also using the dog peri-implantitis model evaluated GBR including a collagen membrane, BBM, an equine bone block with or without recombinant human bone

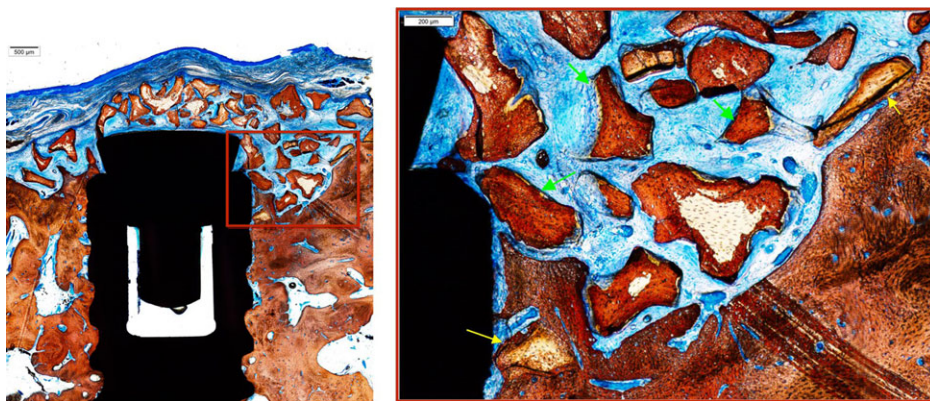


Fig. 4. Peri-implantitis site receiving aPDT/GBR or TTC/GBR. Note BBM particles without evidence of resorption, erosion, or support of bone formation encapsulated in dense connective tissue. (green arrows) and some BBM particles in contact with bone (yellow arrows)

morphogenetic protein-2 (rhBMP-2). They concluded that (i) in all groups, the investigations failed to predictably obtain complete defect resolution, (ii) the surgical procedure was associated with high exposure rates; nevertheless, defect closure approximated 26% (rhBMP-2) and 13%, respectively, of the approximately 5-mm peri-implantitis defects. In other studies, Nociti et al. (2000) compared GBR using a collagen membrane with or without BBM to sham-surgery and BBM stand-alone again using a dog peri-implantitis model without observing significant differences between protocols. In separate studies, the investigators compared a nonresorbable ePTFE membrane with the collagen membrane in the presence or absence of BBM without observing significant effects and differences between protocols (Nociti et al. 2001). Collectively, these studies firmly support the notion that GBR with or without BBM may not provide significant or meaningful outcomes in the

reconstruction of peri-implantitis defects as it relates to bone formation. In comparison, surgical application of rhBMP-2 in an absorbable collagen sponge carrier (rhBMP-2/ACS) as a stand-alone protocol has been shown to support robust clinically relevant bone formation (2.6 mm; 75% defect closure) in a nonhuman primate chronic peri-implantitis model (Hanisch et al. 1997).

Re-osseointegration represents an essential outcome of peri-implantitis reconstruction and may represent an immediate effect of the implant surface decontamination protocol. In the present study, BIC ranged from 28% to 36% of the total defect. Considering regenerated bone only, BIC ranged from 59% to 69% with no significant differences among experimental protocols. Previous studies using aPDT and GBR including an ePTFE membrane produced BIC estimates ranging from 15% to 42% (Shibli et al. 2003, 2006). Disinfection of the peri-implantitis exposed sand-

blasted acid-etched implant surface using chlorhexidine combined with systemic metronidazole, and GBR including an ePTFE membrane produced a BIC estimate of 20% (Wetzel et al. 1999). Similar results have been shown following the use of a collagen membrane for GBR and implant disinfection using chlorhexidine (Namgoong et al. 2015). In other studies, GBR including a collagen membrane and BBM produced BIC estimates approximating 25% (Nociti et al. 2000, 2001). In comparison, surgical application of rhBMP-2/ACS stand-alone produced BIC estimates averaging 40% within newly formed bone, following implant cleansing using a citric acid solution and an air abrasive in the nonhuman primate peri-implantitis model (Hanisch et al. 1997) underscoring the efficacy of this candidate protocol.

The ligature-induced peri-implantitis dog model is well established (Schwarz et al. 2007). Whereas it induces defects similar to that observed in humans (Schwarz et al. 2007), a distribution of heterogeneous defects within and between experimental groups may occur and thus increase variability of the model (Schwarz et al. 2011). The sample size used in studies evaluating treatment for peri-implantitis has ranged between five and nine animals (Persson et al. 1996; Nociti et al. 2001; Shibli et al. 2003, 2006; Schwarz et al. 2011). Herein, a sample size of eight animals was used to account for the expected increased variability inherent to the model reported by others. Eight of 64 implants failed and were not available for histological analysis underscoring the challenges of the model. Whereas studies using mini-pig and nonhuman primate peri-implantitis models

Table 2. Predictor variables for new bone formation and bone-implant contact (BIC) within new bone following antimicrobial tetracycline HCL (TTC) or photodynamic therapy (aPDT) with or without guided bone regeneration (GBR) (n = 8 animals and 55 implants)

	Residual defect depth (mm)				Bone gain (mm)				BIC (%)			
	Coef	95% CI		P-value	Coef	95% CI		P-value	Coef	95% CI		P-value
TTC/aPDT												
No	Ref	–	–	–	Ref	–	–	–	Ref	–	–	–
Yes	0.06	–0.39	0.50	0.79	0.06	–0.15	0.27	0.59	0.00	–0.06	0.07	0.89
GBR												
No	Ref	–	–	–	Ref	–	–	–	Ref	–	–	–
Yes	0.36	–0.18	0.89	0.19	0.21	0.00	0.42	0.05	0.00	–0.12	0.12	0.98
Site												
Buccal	Ref	–	–	–	Ref	–	–	–	Ref	–	–	–
Lingual	–1.39	–2.10	–0.68	>0.001	0.38	0.15	0.61	0.001	0.04	–0.08	0.16	0.55
Mesial	–0.91	–1.40	–0.42	>0.001	0.30	0.15	0.46	>0.001	–0.04	–0.23	0.15	0.68
Distal	–0.91	–1.39	–0.43	>0.001	0.48	0.26	0.69	>0.001	–0.02	–0.16	0.12	0.76
Implant location												
Anterior	Ref	–	–	–	Ref	–	–	–	Ref	–	–	–
Posterior	–0.19	–0.46	0.09	0.18	0.24	0.08	0.41	0.004	0.01	–0.11	0.14	0.85
Implant exposure												
No	Ref	–	–	–	Ref	–	–	–	Ref	–	–	–
Yes	1.67	1.12	2.22	>0.001	–0.59	–0.77	–0.42	>0.001	–0.28	–0.48	–0.08	0.006

have been published (Hickey et al. 1991; Singh et al. 1993; Hanisch et al. 1997; Becker et al. 2011), the vast majority of studies thus far have relied on the dog model.

The clinical relevance of our findings are twofold: (i) Whereas direct comparison between TTC and aPDT with other protocols was not possible due to the study design, it appears that all these methods provide enough implant surface decontamination to allow resolution of the peri-implantitis defect

as long as access to the full extent of the defect is possible and (ii) the use of biomaterials does not seem to enhance bone formation and re-osseointegration, even though from a clinical perspective, biomaterials could serve as a defect fillers, which could have an impact on clinical parameters. Within the limitations of this study, it may be concluded that both antimicrobial protocols stand-alone or combined with GBR using BBM and a collagen membrane allowed

similar and partial resolution of the peri-implantitis defects without significant differences among protocols.

Conflict of interest

The authors declare that they have no conflict of interest.

References

- Becker, S.T., Doerfer, C., Graetz, C., De Buhr, W., Wiltfang, J. & Podschun, R. (2011) A pilot study: microbiological conditions of the oral cavity in minipigs for peri-implantitis models. *Laboratory Animals* **45**: 179–183.
- Berglundh, T., Zitzmann, N.U. & Donati, M. (2011) Are peri-implantitis lesions different from periodontitis lesions? *Journal of Clinical Periodontology* **38**(Suppl. 11): 188–202.
- Blay, A., Blay, C.C., Tunchel, S., Gehrke, S.A., Shibli, J.A., Groth, E.B. & Zetzell, D.M. (2015) Photobiomodulation on dental implant osseointegration: removal torque and resonance frequency analysis in rabbits. *Journal of Oral Implantology* **42**: 316–320.
- Braham, P., Herron, C., Street, C. & Darveau, R. (2009) Antimicrobial photodynamic therapy may promote periodontal healing through multiple mechanisms. *Journal of Periodontology* **80**: 1790–1798.
- Carcuac, O., Abrahamsson, I., Albouy, J.P., Linder, E., Larsson, L. & Berglundh, T. (2013) Experimental periodontitis and peri-implantitis in dogs. *Clinical Oral Implants Research* **24**: 363–371.
- Carcuac, O., Abrahamsson, I., Charalampakis, G. & Berglundh, T. (2015) The effect of the local use of chlorhexidine in surgical treatment of experimental peri-implantitis in dogs. *Journal of Clinical Periodontology* **42**: 196–203.
- Carcuac, O. & Berglundh, T. (2014) Composition of human peri-implantitis and periodontitis lesions. *Journal of Dental Research* **93**: 1083–1088.
- Derks, J., Schaller, D., Hakansson, J., Wennstrom, J.L., Tomasi, C. & Berglundh, T. (2016) Effectiveness of implant therapy analyzed in a Swedish population: prevalence of peri-implantitis. *Journal of Dental Research* **95**: 43–49.
- Derks, J. & Tomasi, C. (2015) Peri-implant health and disease. A systematic review of current epidemiology. *Journal of Clinical Periodontology* **42** (Suppl. 16): S158–S171.
- Donath, K. & Breuner, G. (1982) A method for the study of undecalcified bones and teeth with attached soft tissues. The Sage-Schliff (sawing and grinding) technique. *Journal of Oral Pathology* **11**: 318–326.
- Dortbudak, O., Haas, R., Bernhart, T. & Mailath-Pokorny, G. (2001) Lethal photosensitization for decontamination of implant surfaces in the treatment of peri-implantitis. *Clinical Oral Implants Research* **12**: 104–108.
- Esposito, M., Felice, P. & Worthington, H.V. (2014) Interventions for replacing missing teeth: augmentation procedures of the maxillary sinus. *Cochrane Database Systematic Review* **5**: CD008397. doi:10.1002/14651858.CD008397.pub2.
- Esposito, M., Grusovin, M.G. & Worthington, H.V. (2012) Interventions for replacing missing teeth: treatment of periimplantitis. *Cochrane Database of Systematic Reviews* **1**: CD004970. doi:10.1002/14651858.CD004970.pub5.
- Hanisch, O., Tatakis, D.N., Boskovic, M.M., Rohrer, M.D. & Wikesjö, U.M. (1997) Bone formation and reosseointegration in peri-implantitis defects following surgical implantation of rhBMP-2. *International Journal of Oral and Maxillofacial Implants* **12**: 604–610.
- Hickey, J.S., O'Neal, R.B., Scheidt, M.J., Strong, S.L., Turgeon, D. & Van Dyke, T.E. (1991) Microbiologic characterization of ligature-induced peri-implantitis in the microswine model. *Journal of Periodontology* **62**: 548–553.
- Kilkenny, C., Browne, W., Cuthill, I.C., Emerson, M., Altman, D.G. & Group, N.C. R.R.G.W. (2010) Animal research: reporting in vivo experiments: the ARRIVE guidelines. *British Journal of Pharmacology* **160**: 1577–1579.
- Lang, N.P., Berglundh, T. & Working Group 4 of Seventh European Workshop on, P. (2011) Periimplant diseases: where are we now?—Consensus of the Seventh European Workshop on Periodontology. *Journal of Clinical Periodontology* **38**(Suppl. 11): 178–181.
- Levy, S.B. & Marshall, B. (2004) Antibacterial resistance worldwide: causes, challenges and responses. *Nature Medicine* **10**: S122–S129.
- Lin, L.I.-K. (2000) A note on the concordance correlation coefficient. *Biometrics* **56**: 324–325.
- Lulic, M., Leiggner Gorog, I., Salvi, G.E., Ramseier, C.A., Mattheos, N. & Lang, N.P. (2009) One-year outcomes of repeated adjunctive photodynamic therapy during periodontal maintenance: a proof-of-principle randomized-controlled clinical trial. *Journal of Clinical Periodontology* **36**: 661–666.
- Mayer, L., Gomes, F.V., Carlsson, L. & Gerhardt-Oliveira, M. (2015) Histologic and resonance frequency analysis of peri-implant bone healing after low-level laser therapy: an in vivo study. *International Journal of Oral and Maxillofacial Implants* **30**: 1028–1035.
- Moraschini, V., Poubel, L.A., Ferreira, V.F. & Barboza Edos, S. (2015) Evaluation of survival and success rates of dental implants reported in longitudinal studies with a follow-up period of at least 10 years: a systematic review. *International Journal of Oral and Maxillofacial Surgery* **44**: 377–388.
- Moreira, A.L., Novaes, A.B., Jr., Grisi, M.F., Taba, M., Jr., Souza, S.L., Palioto, D.B., de Oliveira, P.G., Casati, M.Z., Casarin, R.C. & Messoria, M.R. (2015) Antimicrobial photodynamic therapy as an adjunct to non-surgical treatment of aggressive periodontitis: a split-mouth randomized controlled trial. *Journal of Periodontology* **86**: 376–386.
- Namgoong, H., Kim, M.D., Ku, Y., Rhyu, I.C., Lee, Y.M., Seol, Y.J., Gu, H.J., Susin, C., Wikesjö, U.M. & Koo, K.T. (2015) Bone reconstruction after surgical treatment of experimental peri-implantitis defects at a sandblasted/acid-etched hydroxyapatite-coated implant: an experimental study in the dog. *Journal of Clinical Periodontology* **42**: 960–966.
- Nociti, F.H., Jr., Caffesse, R.G., Sallum, E.A., Machado, M.A., Stefani, C.M. & Sallum, A.W. (2000) Evaluation of guided bone regeneration and/or bone grafts in the treatment of ligature-induced peri-implantitis defects: a morphometric study in dogs. *Journal of Oral Implantology* **26**: 244–249.
- Nociti, F.H., Jr., Machado, M.A., Stefani, C.M. & Sallum, E.A. (2001) Absorbable versus nonabsorbable membranes and bone grafts in the treatment of ligature-induced peri-implantitis defects in dogs: a histometric investigation. *International Journal of Oral and Maxillofacial Implants* **16**: 646–652.
- Nyman, S., Lang, N.P., Buser, D. & Bragger, U. (1990) Bone regeneration adjacent to titanium dental implants using guided tissue regeneration: a report of two cases. *International Journal of Oral and Maxillofacial Implants* **5**: 9–14.
- Park, J.B. (2012) Treatment of peri-implantitis with deproteinised bovine bone and tetracycline: a case report. *Gerodontology* **29**: 145–149.
- Persson, L.G., Araujo, M.G., Berglundh, T., Grondahl, K. & Lindhe, J. (1999) Resolution of peri-implantitis following treatment. An experimental study in the dog. *Clinical Oral Implants Research* **10**: 195–203.
- Persson, L.G., Ericsson, I., Berglundh, T. & Lindhe, J. (1996) Guided bone regeneration in the

- treatment of periimplantitis. *Clinical Oral Implants Research* 7: 366–372.
- Persson, L.G., Ericsson, I., Berglundh, T. & Lindhe, J. (2001) Osseointegration following treatment of peri-implantitis and replacement of implant components – an experimental study in the dog. *Journal of Clinical Periodontology* 28: 258–263.
- Qin, Y., Luan, X., Bi, L., He, G., Bai, X., Zhou, C. & Zhang, Z. (2008a) Toluidine blue-mediated photoinactivation of periodontal pathogens from supragingival plaques. *Lasers in Medical Science* 23: 49–54.
- Qin, Y.L., Luan, X.L., Bi, L.J., Sheng, Y.Q., Zhou, C.N. & Zhang, Z.G. (2008b) Comparison of toluidine blue-mediated photodynamic therapy and conventional scaling treatment for periodontitis in rats. *Journal of Periodontal Research* 43: 162–167.
- Ramos, U.D., Ayub, L.G., Reino, D.M., Grisi, M.F., Taba, M., Jr., Souza, S.L., Palioto, D.B. & Novaes, A.B., Jr. (2015) Antimicrobial Photodynamic therapy as an alternative to systemic antibiotics: results from a double-blind, randomized, placebo-controlled, clinical study on type 2 diabetics. *Journal of Clinical Periodontology* 43: 147–155.
- Renvert, S., Polyzois, I. & Maguire, R. (2009) Re-osseointegration on previously contaminated surfaces: a systematic review. *Clinical Oral Implants Research* 20(Suppl. 4): 216–227.
- Roccuzzo, M., Bonino, F., Bonino, L. & Dalmaso, P. (2011) Surgical therapy of peri-implantitis lesions by means of a bovine-derived xenograft: comparative results of a prospective study on two different implant surfaces. *Journal of Clinical Periodontology* 38: 738–745.
- Romanos, G., Ko, H.H., Froum, S. & Tarnow, D. (2009) The use of CO₂ laser in the treatment of peri-implantitis. *Photomedicine and Laser Surgery* 27: 381–386.
- Roos-Jansaker, A.M., Renvert, H., Lindahl, C. & Renvert, S. (2007) Surgical treatment of peri-implantitis using a bone substitute with or without a resorbable membrane: a prospective cohort study. *Journal of Clinical Periodontology* 34: 625–632.
- Salvi, G.E., Persson, G.R., Heitz-Mayfield, L.J., Frei, M. & Lang, N.P. (2007) Adjunctive local antibiotic therapy in the treatment of peri-implantitis II: clinical and radiographic outcomes. *Clinical Oral Implants Research* 18: 281–285.
- Schwarz, F., Herten, M., Sager, M., Bieling, K., Sculean, A. & Becker, J. (2007) Comparison of naturally occurring and ligature-induced peri-implantitis bone defects in humans and dogs. *Clinical Oral Implants Research* 18: 161–170.
- Schwarz, F., Sahm, N., Bieling, K. & Becker, J. (2009) Surgical regenerative treatment of peri-implantitis lesions using a nanocrystalline hydroxyapatite or a natural bone mineral in combination with a collagen membrane: a four-year clinical follow-up report. *Journal of Clinical Periodontology* 36: 807–814.
- Schwarz, F., Sahm, N., Mihatovic, I., Golubovic, V. & Becker, J. (2011) Surgical therapy of advanced ligature-induced peri-implantitis defects: cone-beam computed tomographic and histological analysis. *Journal of Clinical Periodontology* 38: 939–949.
- Shibli, J.A., Martins, M.C., Nociti, F.H., Jr., Garcia, V.G. & Marcantonio, E., Jr. (2003) Treatment of ligature-induced peri-implantitis by lethal photosensitization and guided bone regeneration: a preliminary histologic study in dogs. *Journal of Periodontology* 74: 338–345.
- Shibli, J.A., Martins, M.C., Ribeiro, F.S., Garcia, V.G. & Nociti, F.H. (2006) Lethal photosensitization and guided bone regeneration in treatment of peri-implantitis: an experimental study in dogs. *Clinical Oral Implants Research* 17: 273–281.
- Singh, G., Oneal, R.B., Brennan, W.A., Strong, S.L., Horner, J.A. & Vandyke, T.E. (1993) Surgical-treatment of induced peri-implantitis in the micro pig – clinical and histological analysis. *Journal of Periodontology* 64: 984–989.
- Tavares, A., Carvalho, C.M., Faustino, M.A., Neves, M.G., Tome, J.P., Tome, A.C., Cavaleiro, J.A., Cunha, A., Gomes, N.C., Alves, E. & Almeida, A. (2010) Antimicrobial photodynamic therapy: study of bacterial recovery viability and potential development of resistance after treatment. *Marine Drugs* 8: 91–105.
- Tenenbaum, H., Bogen, O., Severac, F., Elkaim, R., Davideau, J.L. & Huck, O. (2016) Long-term prospective cohort study on dental implants: clinical and microbiological parameters. *Clinical Oral Implants Research* doi: 10.1111/clr.12764. [Epub ahead of print].
- de Waal, Y.C., Raghoobar, G.M., Meijer, H.J., Winkel, E.G. & van Winkelhoff, A.J. (2015) Implant decontamination with 2% chlorhexidine during surgical peri-implantitis treatment: a randomized, double-blind, controlled trial. *Clinical Oral Implants Research* 26: 1015–1023.
- Wetzel, A.C., Vlassis, J., Caffesse, R.G., Hammerle, C.H. & Lang, N.P. (1999) Attempts to obtain re-osseointegration following experimental peri-implantitis in dogs. *Clinical Oral Implants Research* 10: 111–119.

Supporting Information

Additional Supporting Information may be found in the online version of this article:

The ARRIVE Guidelines Checklist.