



# Comparison of Different Periimplantitis Treatment Methods

Viktor E. Karapetian, Jörg Neugebauer, Claudia E. Clausnitzer, Joachim E. Zöller

University to Cologne, Germany



## Introduction

This study concerns the periimplantitis treatment with different conventional, surgical and photodynamic methods on edentulous patients and patients with residual teeth. The following cases described how we took care of patients with periimplant inflammation. Before treatment it seemed to be important to verify the bacterial status. The microbiological examination showed the presence of periodontal pathogenic bacteria (*A. actinomycetemcom.*, *P. gingivalis*, *P. intermedia*, *B. forsythus*). However it is not only necessary to treat the periimplantitis but also to reconstruct the inflammation caused defects<sup>1</sup>.

## Purpose

The microbiological examination was done to show how residual, with periodontal defect affected teeth can set up a periimplantitis while reinforcing the implant site. The purpose of the treatment method shown below, was not only to improve the treatment of periimplantitis, but also to show the connection between bacteria and different treatment effectiveness. Also it was to verify which, treatment method could achieve the best result in reducing the initial bacteria population and which method could prevent best a long term disinfection and re-colonization to help fighting the periimplant inflammation.

## Material & Method

25 Patients with periimplantitis lesions had been treated with different methods over a period of 6 month. Before treatment there was a clinical, radiographic and microbiological examination off by periimplantitis affected implants. The microbiological examination showed the presence of periodontal pathogenic bacteria (*A. actinomycetemcom.*, *P. gingivalis*, *P. intermedia*, *B. forsythus*). Loss of osseous tissue around the implants was measured by radiographic analysis and was documented by photography to show the effect of the periimplantitis treatment.

Also the change of bacterial colonization was examined before and after treatment. The surgical treatment included the opening of the implant site, cleaning and disinfecting the local defect and replacing the lost bone by using a bone replacement graft (PepGen P-15<sup>®</sup>, DENTSPLY Friadent, Germany).

The **photodynamic treatment** light decontamination (Helbo-Medizin-Technik, Austria)

The **antibiotic treatment** included not only the mechanical cleaning of the implant surface, but also the use of local antibiotics (Atridox<sup>®</sup>, Atrix Laboratories GmbH, Germany).

During the **ozone therapy** the mechanical cleaning was supported by the use of the OzonyTron<sup>®</sup> device for bacterial decontamination.

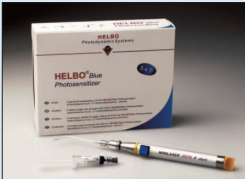

Fig. 1.1: Diode soft-laser (Helbo-Medizin-Technik, Austria)

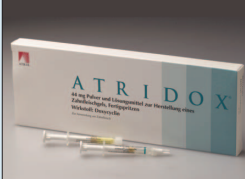

Fig. 1.2: Atridox<sup>®</sup>-powder and liquid syringe (Atrix Laboratories GmbH, Germany)

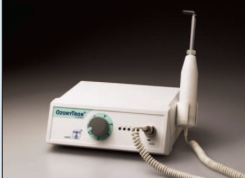

Fig. 1.3: OzonyTron<sup>®</sup> Device (Mymed, Germany)

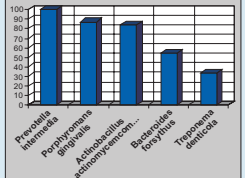


Chart 1: Bacteria frequency distribution on periimplantitis sites in %.

## Helbo

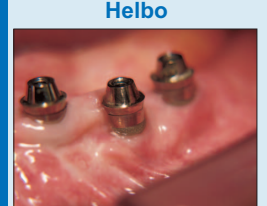


Fig. 2.1: Vestibular recession at a lower jaw implant

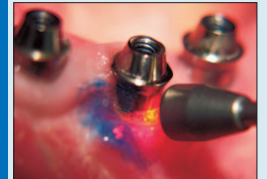

Fig. 2.2: Decontamination with diode laser (Helbo-Medizin-Technik, Austria)

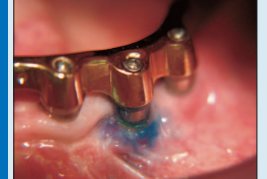

Fig. 2.3: Situation after 2 days with residual Helbo-blue<sup>®</sup> (Helbo-Medizin-Technik, Austria)

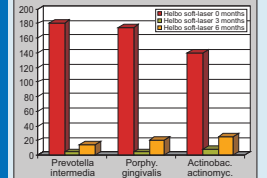


Chart 2: 92% bacteria reduction before and after photodynamic therapy (x104 cbu)

## Desinfection Treatment

### Atridox

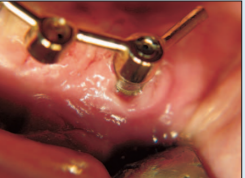

Fig. 3.1: Inflammation at a lower jaw implant

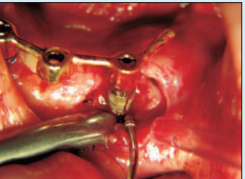

Fig. 3.2: Intraoperative defect situation with loss of vestibular bone

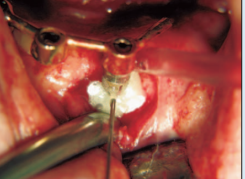


Fig. 3.3: Application of local antibiotic Atridox<sup>®</sup> (Atrix Laboratories GmbH, Germany)

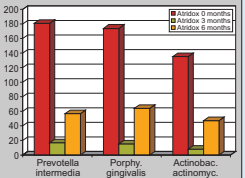


Chart 3: Mean bacteria reduction of 71% for 3 months and re-increase after 6 months (x104 cbu)

### Ozony

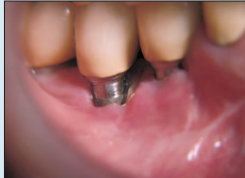

Fig. 4.1: Inflammatory process at a lower jaw implant

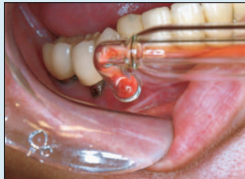


Fig. 4.2: OzonyTron<sup>®</sup> ozone treatment (Mymed, Germany)

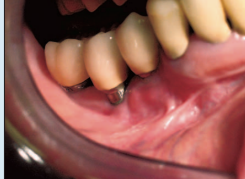

Fig. 4.3: Healthy clinical situation 2 weeks after treatment with OzonyTron<sup>®</sup> (Mymed, Germany)

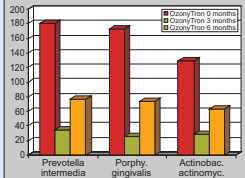


Chart 4: Mean bacteria reduction of 64% for 3 months and re-increase after 6 months (x104 cbu)

### Surgery

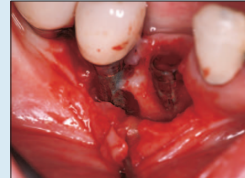

Fig. 5.1: Intraoperative site of a periimplant bone defect with granulation tissue

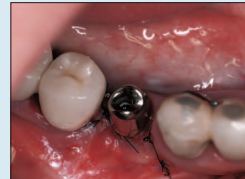

Fig. 5.2: Situation after scaling, bone remodelling and closure

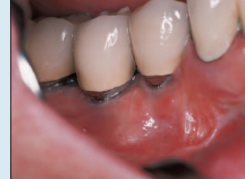

Fig. 5.3: Postoperative situation after 2 weeks

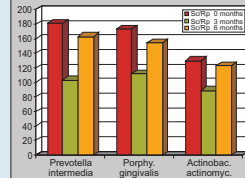


Chart 5: 17% bacteria reduction before and after scaling and implant-surface planing (x104 cbu)

## Reconstruction

### PepGen P-15

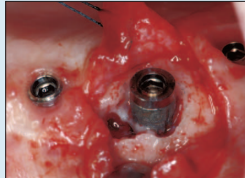


Fig. 6.1: Open periimplant lesion after pre-operative treatment with Atridox

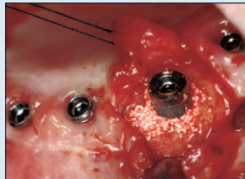

Fig. 6.2: Easy application of PepGen P-15<sup>®</sup> bone graft material

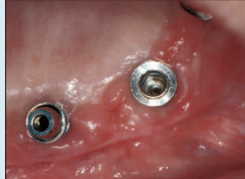

Fig. 6.3: Clinical situation after 3 months with stable soft and hard tissue regeneration

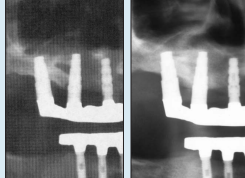


Fig. 6.4: X-ray before treatment and after 3 months

## Results

The treatment results showed that all methods could reduce bacterial colonization of an acutely periimplant inflammation. By using the diode laser light, bacteria re-colonization showed the lowest increase after 6 months. To achieve this results, soft-laser treatment had to be combined with surgical opening of the implant site for cleaning a disinfecting the local defect. The second most effective decontamination method was the combination of surgical and antibiotic treatment. The combination of ozone and surgical therapy was less effective than the first two described treatment methods. Cleaning and implant-surface polishing alone does not show very good results in reducing the bacteria population. Reconstructing the loss of periimplant bone with PepGen P-15<sup>®</sup>, showed good results in this study.

## Discussion

Regeneration of an osseous periimplantitis lesion seems to be a very difficult problem. So the most important decision is to reduce pathogenic factors before implantation<sup>1</sup>. Patients with serious periodontal defects, diabetics or inadequate oral hygiene should be detected and pre-treated before implantation. In case of the small number of patients in this study can only give a hint for the right treatment method, even if we had success stopping the inflammation.

## Conclusion

The treatment results showed that all methods are useful for periimplantitis treatment, but total oral decontamination and prevention of re-colonization with periodontal pathogenic bacteria seems to be at least most important for a successful treatment<sup>1</sup>. Decontamination with the Helbo diode laser light showed a more effective result than the OzonyTron<sup>®</sup> decontamination or the Atridox<sup>®</sup> doxycycline ointment. Cleaning and implant-surface polishing alone does not show very good results in reducing the bacteria population<sup>1</sup>. Reconstruction of the periimplantitis lesion showed a good success by using PepGen P-15<sup>®</sup>.

## References

- Ericsson I, Persson LG, Berglundh T, Edford T, Lindhe J.: The effect of antimicrobial therapy on periimplantitis lesions. An experimental study in the dog. Clin Oral Implants Res. 1998 Oct;9(3):228-38.
- El Charaf ES, Jarabou ZN.: Regeneration of an osseous peri-implantitis lesion. Periodontol Clin Invest. 2002; Fall(24):112-15.
- Dorflinger G, Haas R, Mallya-Pokorny G.: Biofilm/loss of bone matrix cells with a diode soft laser. Clin Oral Implants Res. 2002 Dec;13(6):64-9.
- Romanos G, Nertwig GH.: Diode laser (800 nm) in oral and maxillofacial surgical procedures. Clinical observations based on clinical applications. J Clin Laser Med Surg. 1999 Oct;7(5):193-7.

Bridging the Future with Implants

19th Annual Meeting of the Academy of Otolaryngology  
March 18-20, 2004, San Francisco, USA  
Dr. Viktor E. Karapetian  
University of Cologne  
Dept. of Otorhinolaryngology, Head and Neck Surgery  
Krankenhaus St. Zofen  
Krankenhaus St. Zofen, D-50551 Köln, Germany  
www.klinik.uni-koeln.de