

## CURRENT ASPECTS IN THE TREATMENT OF PERIODONTALLY DISEASED PATIENTS WITH ANGULATED IMPLANTS

# Treatment of patients with chronic periodontal disease

DR JÖRG NEUGEBAUER<sup>1,3</sup>, STEFAN ADLER<sup>2</sup>, DR FRANK KISTLER<sup>1</sup>, DR STEFFEN KISTLER<sup>1</sup>

Implant treatment on patients with chronic periodontal disease is still viewed with scepticism by some dentists. In addition to the presence of chronic inflammation parameters on the natural periodontal system, the risk of early implant failure and of biological complications is viewed critically [23]. Although we have reports covering many years of experience with implant treatment in periodontally compromised patients, the relevant treatment concepts are still highly divergent, or the patient is denied implant therapy due to this relative contraindication [21]. The incidence of periodontal disease has increased steadily in recent years. Surgical and prosthetic treatment planning must be supplemented by the management of the periodontal tissues before and during implant treatment as well as at recall in order to ensure long-term success [11].

## Microbiological load

An aggressive microbiological environment may lead to peri-implantitis with acute inflammation requiring invasive forms of treatment that may even include explantation, depending on the stage of the disease.

In classical periodontal therapy, supportive systemic or local antibiotic therapy is generally recommended, but this requires a strict indication because of possible systemic side effects, which specifically include the development of hypersensitivity and resistance even at lower dosage levels.

Various alternative methods have been presented in recent years that follow a photodynamic or photothermal approach. Unfortunately, these treatments were not always effectively evaluated scientifically before their launch, so only selected methods can be justified for clinical use [7,8]. Antimicrobial photodynamic therapy (aPDT) is a system that has now been scientifically documented for periodontal use. In aPDT, a highly concentrated, sterile dye is activated according to the wavelength of the photosensitizer, using low-level energy for a sufficient time period [4,5,20,24]. This reduces the pathogen spectrum and facilitates a physiological recolonization. The low-level laser supports tissue

regeneration by its photobiological effect and additionally helps stabilize the periodontal situation (Figs. 1 to 4).

## Implant/prosthetic treatment planning

Using a reduced number of implants by definition reduces the peri-implantitis risk, as the restoration will be supported by fewer implants [28]. Here we can refer to the *Brånemark* group's many decades of experience with full-arch restorations, where the entire dentition in a jaw is replaced by a single superstructure [12].

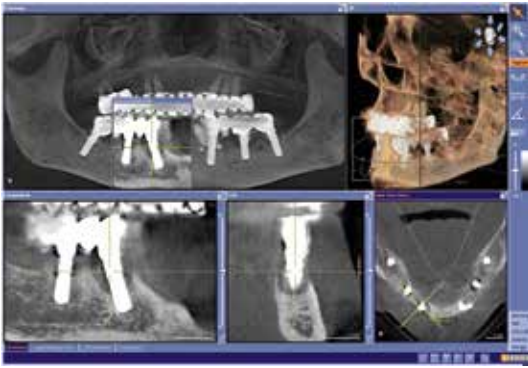A combination of immediate restoration and immediate implant placement when removing the last periodontally compromised teeth may facilitate an effective fixed provisional restoration, where the patient does not have to suffer an emotionally stressful phase wearing a removable dental prosthesis [2].

Depending on the existing bone supply and the need for additional augmentation, immediate restoration is not always mandatory. Especially if existing teeth or implants can be used as supporting elements, chewing comfort will not be unduly limited. To achieve this, expectations and individual therapeutic options should be discussed with the patient

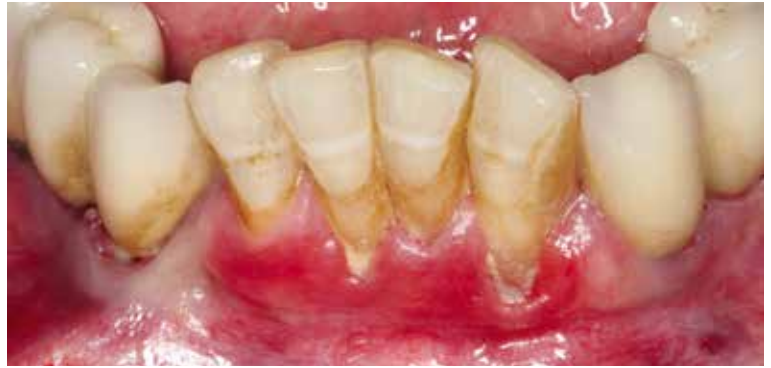<sup>1</sup> Dr Bayer, Dr Kistler and Dr Elbertzhagen, Private Practice, Landsberg am Lech, Germany

<sup>2</sup> Implant Dental Consult, Landsberg am Lech, Germany

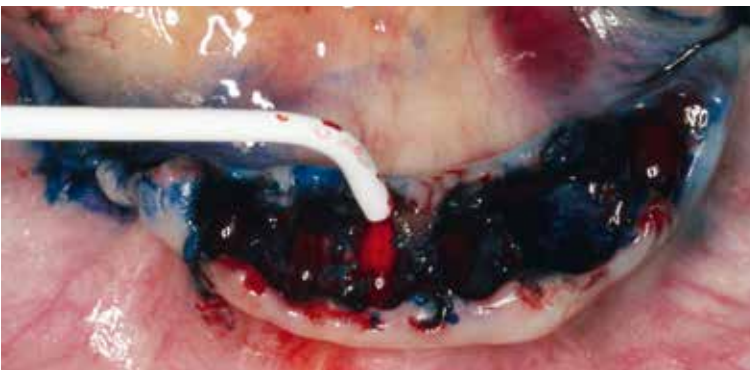<sup>3</sup> Interdisciplinary Clinic for Oral Surgery and Implantology, Department of Dentistry and Oral and Maxillofacial Surgery of the University of Cologne, Germany



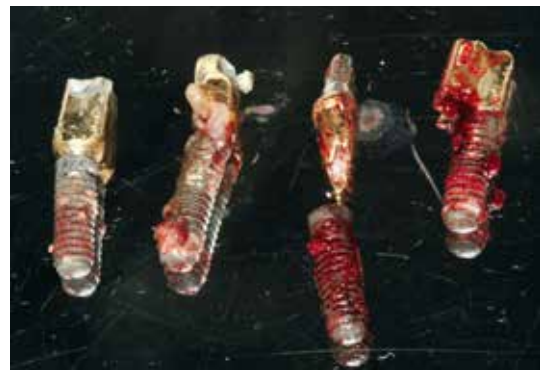1 | CBCT for evaluating the bone defects and the available bone volume for possible retromolar bone harvesting.



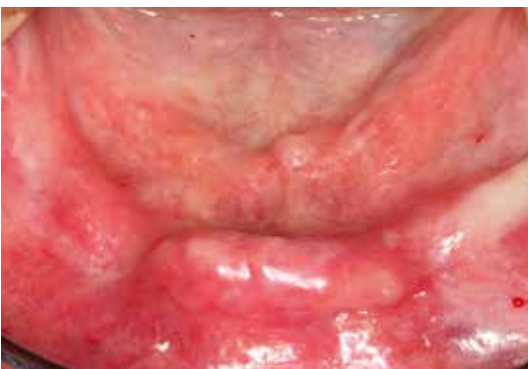2 | Clinical situation. Pronounced chronic periodontal disease in the anterior mandible.



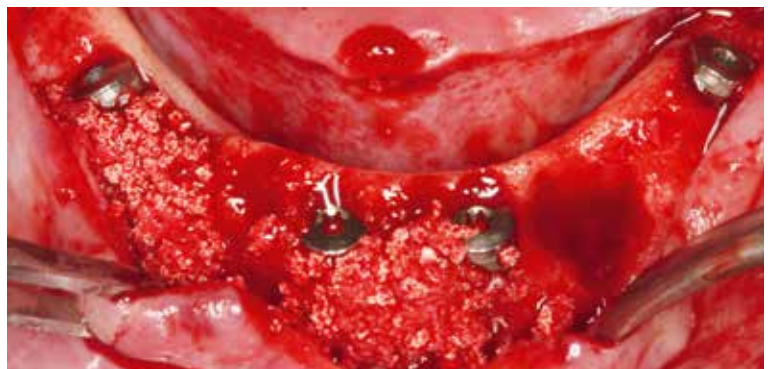
3 | Intraoperative situation after extraction and explantation with aPDT disinfection (Helbo; bredent medical, Senden, Germany).



4 | The removed implants show pronounced concretions in the crestal region.



5 | Rimose alveolar ridge with healed soft tissue, eight weeks after explantation.



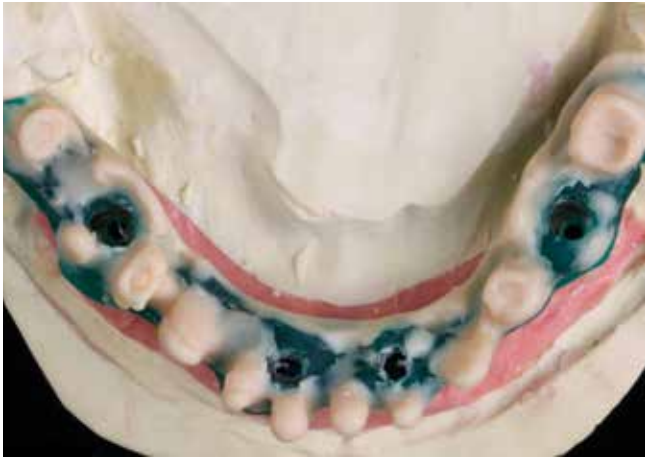6 | Implant placement (blueSky; bredent medical) in an angulated position with lateral bone augmentation near the implants and remaining explantation sockets.

well ahead of time, in the early planning stage. So that a full-arch restoration can be supported by a reduced number of implants, it is often necessary to tilt the posterior implants to an angle of approximately  $35^\circ$  [17].

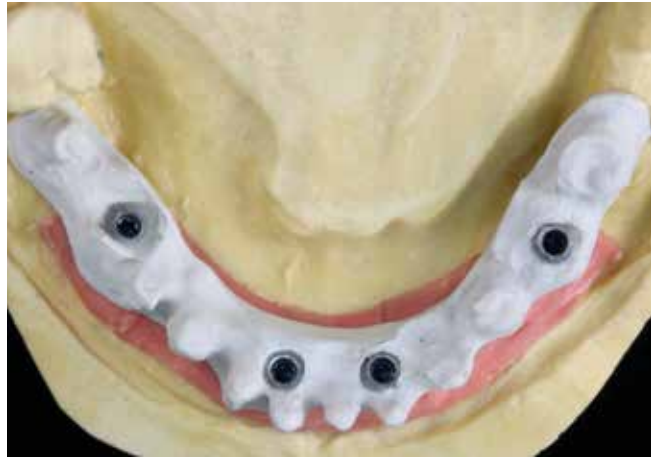
This extends the anterior-posterior support area as far as possible without causing injury to the anatomical structures in the mandible (mental foramen) or the maxilla (configuration of the floor of the maxillary sinus). The criteria for immediate

restoration (or the length of the healing period for submerged healing) are based on the anatomical situation, the general health of the patient and the specific recommendations that apply to the respective implant system [19].

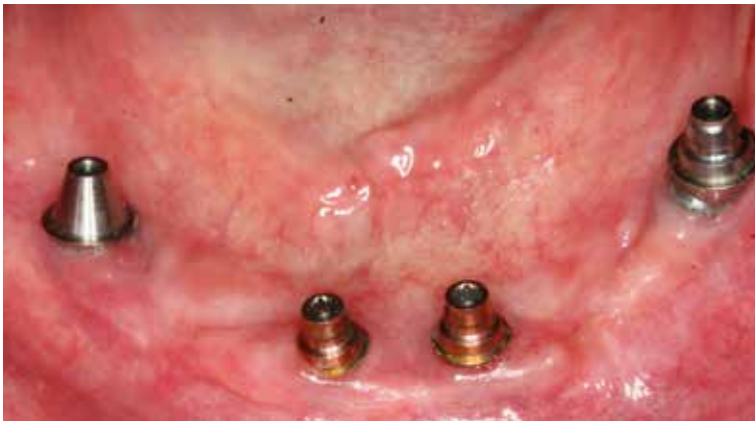By optimizing the implant surfaces, which today are usually abraded and hot-etched, the definitive restoration can be delivered after six to eight weeks – both in immediate provisionalization cases and in submerged healing (Figs. 5 and 6).



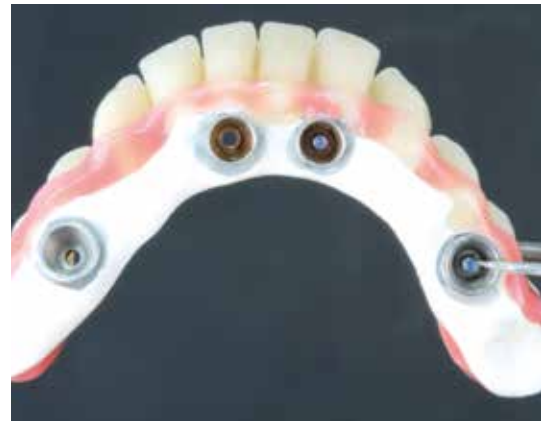7 | Modelling a framework for rehabilitation with a full-arch restoration on four implants.



8 | Detail finish of the framework made of a high-performance polymer (BioHPP; bredent medical) before applying the opaque.



9 | No soft-tissue irritation is present at the time of delivering the denture with its reduced-diameter abutments (SKY uni.cone 3,5 N; bredent medical).



10 | Detail finish of the resin bridge with a basal contact surface made of PEEK.

### Restorative treatment

Dental technicians and dentists appreciate abutments that are easy to place and connect and that provide a wide contact surface for the superstructure [3]. They facilitate a standardized procedure at the mucosal level without requiring extensive verification of the correct abutment positions. In full-arch rehabilitations, providing a classic restoration with a cast framework is time-consuming and associated with high laboratory cost, with the result that the use of adhesive bases or CAD/CAM frameworks has become established in recent years [9,13].

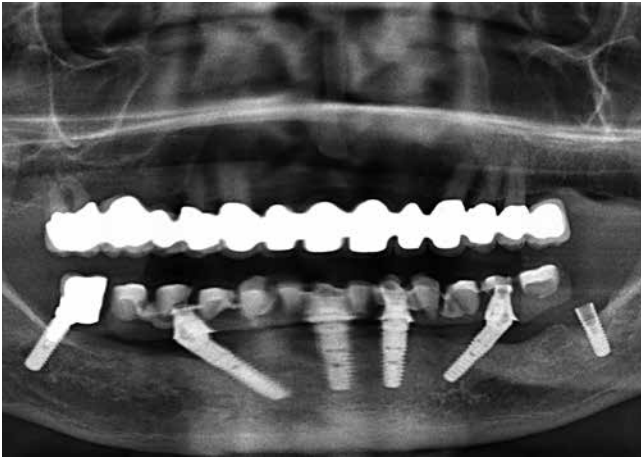
CAD/CAM framework designs need meticulous preparation, as the ceramic veneer requires a uniform veneering thickness to avoid chipping [1]. If the occlusion is not recorded with the necessary precision, requiring subsequent modification, this usually means that the restoration will require

more frequent repairs due to the chipping that may occur [14,22].

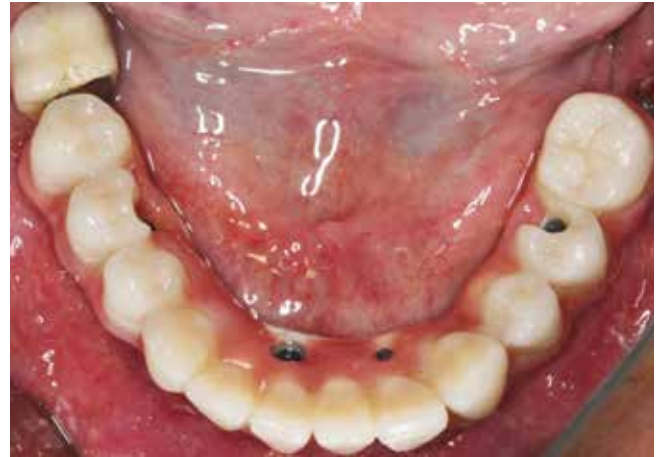There are two preventive approaches that can be considered established. A metal framework can be fabricated using CAD/CAM. Alternatively, the framework may be produced from a highly elastic resin [15,16]. High-performance polymers can be processed by pressing – no elaborate CAD/CAM design programmes or milling procedures are required. By adding a ceramic filler, the material achieves high strength and a modulus of elasticity similar to that of natural bone, which practically eliminates framework fractures [26].

Compared to zirconia frameworks, these resin frameworks are significantly lighter, which patients perceive as comfortable because the foreign-body sensation is reduced. Since the material also has a very dense structure, water absorption is very low. Surface changes associated with soft-tissue irrita-





11 | X-ray inspection before the removal of implant 37 (the radiolucency at implant 42 is projection-induced).



12 | Bridge reinserted after explantation. The screw access canals are not sealed yet.

tion or the inclusion of particles that cause discoloration are therefore not expected. On the basal aspect, the definitive framework may be left in continuous contact with the mucosa, as the high-performance polymer exhibits a very favourable soft-tissue reaction [10,27].

It should be noted, however, that the PEEK surface is susceptible to mechanical roughening by prophylactic measures. Therefore, the framework should be completely encased with the same resin as that used for veneering in all regions not in direct contact with the mucosa.

The frameworks are veneered, after conditioning with a special opaque and bonding system, with a fixation composite, so that the prefabricated resin veneers can be permanently attached to the framework [25]. In addition to stable support, the configuration of the abutments is important for the framework design. At the centre of masticatory activity, it is therefore advisable to use wide abutments, rendering the contact surfaces of the superstructure almost identical to the buccolingual width of the dental arch. However, this can lead to problems, especially in the anterior mandible, because the patients perceive an encroachment on their tongue space following the loss of their mandibular anterior teeth. Reduced-diameter abutments have the advantage that they ensure a stable support of the superstructure while being relatively slender in shape (Figs. 7 to 12).

### Recall

At delivery, the screw-retained restoration is seated uniformly and free of tension by alternating the application of torque to the retaining screws. This

avoids tension and deformation and reduces the risk of early screw loosening.

Other possible reasons for early loosening of the retaining screws, in addition to an imperfect fit of the superstructure, include a suboptimal occlusal design and articulation [18]. Therefore, the occlusion should be re-checked at a follow-up appointment two to eight weeks after delivery.

When delivering combination restorations – screw-retained on the angulated abutments and a semi-permanently cemented on the anterior fixtures – the retaining screws must be tightened alternately on the right and left, so that the cementing on the anterior structures can also take place uniformly.

It is important to check not only the occlusion and articulation at the recall appointments but also the periodontal status of the antagonistic dentition to prevent displacement within the oral environment, possibly leading to peri-implant mucositis – which in turn would need to be treated with aPDT again [6]. ■

To find the list of references visit the web ([www.teamwork-media.de](http://www.teamwork-media.de)). Follow the link "Literaturverzeichnis" in the left sidebar.

### Contact address

Dr Jörg Neugebauer  
Dr Bayer, Dr Kistler and Dr Elbertzhagen  
Private Practice, Landsberg am Lech  
Von-Kühlmann-Straße 1  
86899 Landsberg am Lech  
Germany  
[neugebauer@implantate-landsberg.de](mailto:neugebauer@implantate-landsberg.de)  
[www.implantate-landsberg.de](http://www.implantate-landsberg.de)