

Adjunctive role of photodynamic therapy in the nonsurgical endodontic retreatment of a molar with grade II furcation involvement

Preeti Jain Pruthi, Neha Yadav¹, Sangeeta Talwar, Arundeeep Kaur Lamba¹, Mahesh Verma²

Departments of Conservative Dentistry and Endodontics, ¹Periodontics and Oral Implantology, ²Prosthodontics, Maulana Azad Institute of Dental Sciences, Delhi, India

ABSTRACT

Endodontic therapy has a high survival rate, but in cases of post-treatment pathosis, retreatment may be required. This case report presents a similar case of endodontic failure which resulted in a coexistent periradicular-periodontal lesion. The case was managed by nonsurgical endodontic retreatment followed by photodynamic therapy in the periodontal region. Satisfactory results were obtained when the case was followed up clinically and radiographically for 18 months.

Key words: Furcation defect, orthograde re treatment, photodynamic therapy

Access this article online

Website: www.jicdro.org

DOI: 10.4103/2231-0754.139104

Quick Response Code:



INTRODUCTION

Recent advances in endodontics and increased patient awareness has resulted in the increased demand of endodontic treatment. An evaluation of the endodontic literature reveals that a significant percentage of root canal-treated teeth do not respond to treatment in a manner consistent with clinical or radiographic success.^[1] When considering treatment for such teeth, significant challenges need to be addressed to attain complete healing of the diseased tooth. Options for re-treatment are non-surgical endodontic or surgical endodontic. The choice of treatment approach should be based upon the patient's clinical situation and preference, operator's experience and skill, the risk of complications, technical feasibility, and cost.^[2] Non-surgical approach is always preferred as surgery is a compromise, unless microorganisms are assumed to be harbored periapically, retreatment is unfeasible or restricted, or a retreatment attempt has failed.

This article reports the management of a patient with persistent periapical lesion in mandibular second molar

with furcation involvement, with the aid of non-surgical endodontic retreatment and photodynamic therapy (PDT) in the furcal region.

REVIEW OF LITERATURE

Up to 85% treatment success has been reported for periapical lesions after endodontic therapy alone,^[3] which implies that most periapical lesions including cysts respond solely to endodontic therapy.^[4] This is explained by the effect of biomechanical preparation on intracanal microbiota,^[5] enzymatic mechanisms,^[6] immunological mechanisms involving neutralization of antigenic toxins,^[7] and breakdown of epithelial lining with involvement of macrophages, non-killer T lymphocytes, and Langerhans cells.^[5]

The traditional debridement procedures have focused primarily on reducing the bacterial load in the periodontal tissues. This can be accomplished either through surgical or nonsurgical procedures, with the occasional adjunctive use of systemic and/or local antimicrobial agents in certain situations. Systemic antibiotics may be useful for those patients who fail to respond adequately to mechanical debridement procedures. Their use is limited due to the emergence of resistant bacteria, development of potential hypersensitivity reactions, and occurrence of side effects.^[8] The development of localized delivery systems that deposit

Address for correspondence:

Dr. Preeti Jain, Department of Conservative Dentistry and Endodontics, 3rd Floor, Maulana Azad Institute of Dental Sciences, MAMC complex, Bahadur Shah Zafar Marg, Delhi - 110 002, India.
E-mail: drpreetijain82@gmail.com

highly concentrated doses of antibiotic and/or antimicrobial agents directly at the site of infection (in the periodontal pocket) have been shown to improve treatment efficacy, while at the same time decreasing side effects and limiting resistance.

More recently, an antimicrobial photodynamic therapy that combines advanced non-thermal diode laser technology with a photosensitizing solution for the treatment of periodontal diseases has been introduced. It not only kills Gram-negative bacteria associated with periodontal disease, but also inactivates those endotoxins that are responsible for tissue destruction, thus greatly improving a patient's chances of healing.^[9] In addition, it does not carry any risks of promoting antibiotic resistance.^[10] In clinical trials, patients receiving aPDT in conjunction with scaling and root planing (SRP) experienced significant improvements over patients treated with SRP only: these benefits included shallower pockets, increased clinical reattachment, and reduced bleeding.^[11]

CASE REPORT

A 27-year-old male patient reported with tenderness in mandibular left second molar. There was a history of previous endodontic treatment along with placement of crown about 1 year back. The patient remained asymptomatic till reappearance of pain and localized gingival swelling. The patient reported with a complaint of dull chronic pain and purulent discharge from the gingiva adjacent to the mandibular molar. All these symptoms precipitated his visit to the hospital.

Clinical examination revealed Grade II furcation involvement of the tooth with the horizontal component of furcation being 6 mm and vertical component being 7 mm [Figure 1]. On radiographic examination, the treated tooth revealed poorly obturated canals and radiolucency at the root apex and in the furcal area [Figure 2]. An informed consent was obtained and the decision for non-surgical retreatment along with periodontal intervention was taken.

After the initiation of phase I periodontal therapy, the crown was removed and access to the root canal system was gained. The previous canal filling was removed with the help of xylene (Fischer Scientific, Mumbai, India) and headstroem files (Dentsply Maillefer Ballaigues). The canals were thoroughly irrigated with 3% sodium hypochlorite, working length was determined [Figure 3] and then canal preparation was done with rotary Protaper files (Dentsply Maillefer Ballaigues) using the crown down technique. During the biomechanical preparation, the canal was repeatedly irrigated with sodium hypochlorite. After a final 17% EDTA rinse and drying of root canal system, 2% chlorhexidine gel was placed in the canals

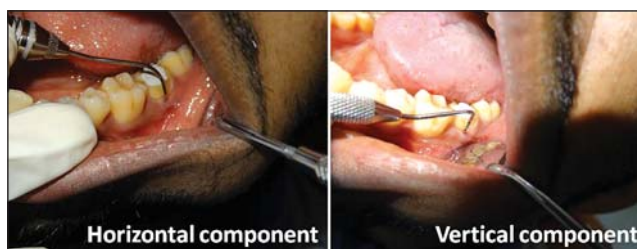


Figure 1: Measurement of horizontal and vertical component of furcation

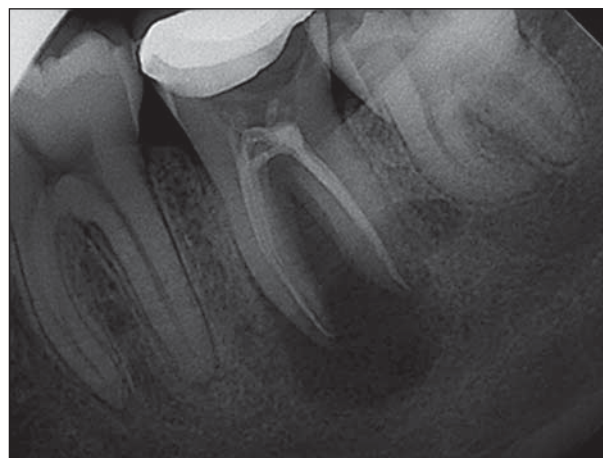

Figure 2: Preoperative radiograph

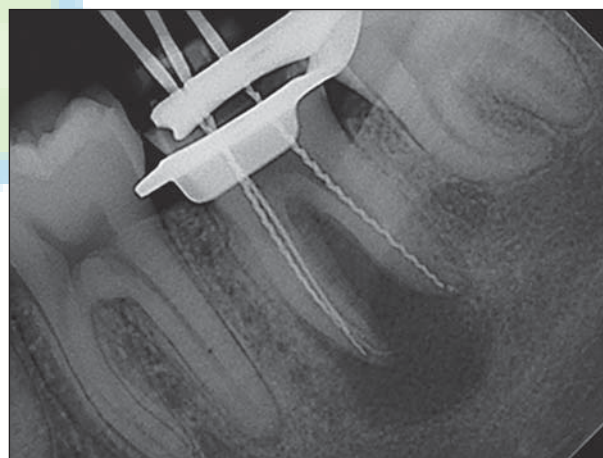


Figure 3: Working length determination radiograph

for 1 week, followed by a dressing of iodine potassium iodide for another week.

Non-surgical periodontal therapy involved the adjunctive use of photodynamic therapy in the furcation defect. Photosensitizer dye (Helbo-Blue, Helbo Photodynamic Systems, Austria) using syringe was injected in the furcation [Figure 4] and was left there for 3 minutes. The furcation was irrigated with normal saline, to remove excess dye. A beam of light was applied from a hand-held, battery-operated diode laser (Helbo's minilaser, Helbo Photodynamic Systems, Austria) using fiber-optic tip (Helbo's 3D Pocket Probe, Helbo

Photodynamic Systems, Austria), at a wavelength of 670 nm and power density of 75 mW/cm², for 1 minute [Figure 5].

The patient was instructed to maintain oral hygiene and recall was scheduled after 1 week. At the recall appointment, the furcation was probed to evaluate the presence of bleeding on probing. Since the bleeding was absent, no further photodynamic therapy was done.

On subsequent appointments when the patient became asymptomatic, the tooth was scheduled for obturation, and the root canal system was obturated with gutta percha and AH plus sealer (De Trey, Konstanz, Germany) [Figure 6]. Probing of the furcation after 1 month revealed a reduction in the horizontal probing depth to 2 mm. On follow-up radiographs at 6 months, 12 months, and 18 months, healing was evident as the radiolucency in the periapical and interradicular region regressed significantly [Figures 7-9].

DISCUSSION

Root canal system anatomy plays a significant role in endodontic success and failure. Although sealing the root

canal system in three dimensions has been shown to be a predictable procedure with a high degree of success, failures can occur after treatment.^[12] Unlike primary endodontic infections, which are polymicrobial in nature, secondary infections involve one or a few bacterial species. *Enterococcus faecalis* is a persistent organism that plays a major role in a high percentage of root canal failures.^[13] In addition, fungi such as *Candida* seem to be more common in the root canals of obturated teeth in which treatment failed.^[14]

Studies have shown that the re-treatment of the failed cases has a higher long-term success with non-surgical approach (83%) as compared to the surgical approach (71.8%).^[15]

The present case had two challenges — endodontic as well as periodontal — based on which, the treatment plan was formulated. The root canals were disinfected using sodium hypochlorite, which is indisputably a gold standard as an endodontic irrigant, but it has a limited role against *E. faecalis*.^[16] Iodine potassium iodide is considered to be an effective intracanal agent against *E. faecalis*. Moreover, chlorhexidine, in a 2% gel or liquid concentration, is

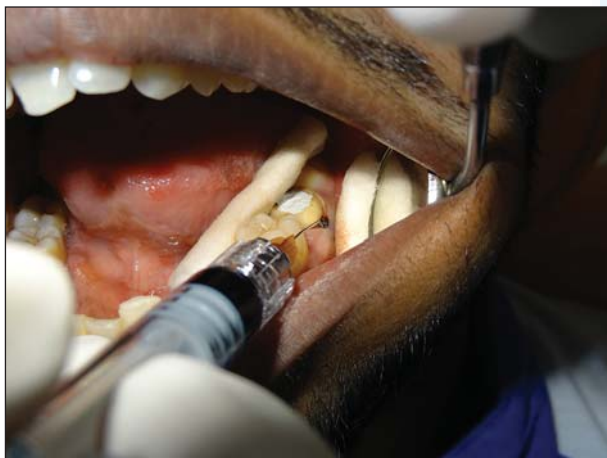

Figure 4: Photo sensitizer dye injection in the furcation

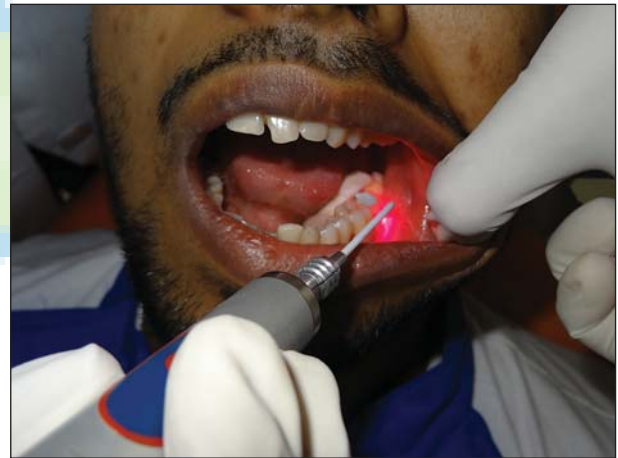

Figure 5: Application of diode laser using fiber optic tip

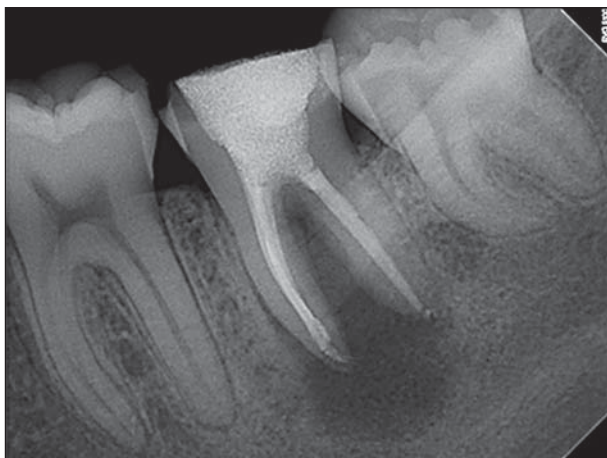


Figure 6: Immediate post obturation radiograph

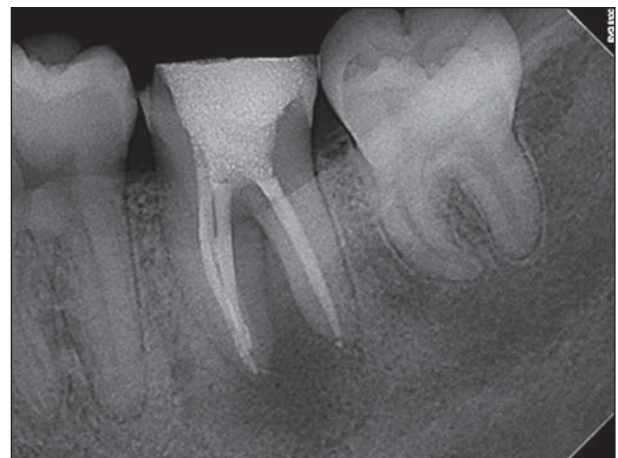

Figure 7: Radiograph at 6 months

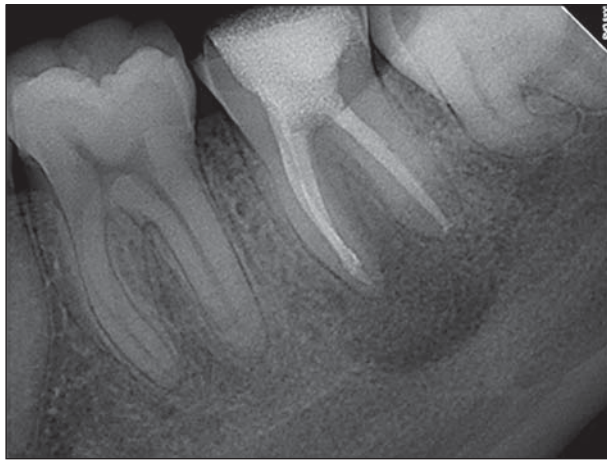

Figure 8: Radiograph at 12 months

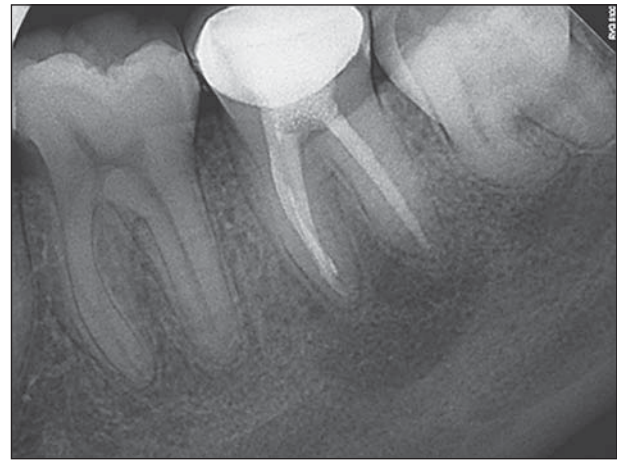

Figure 9: Radiograph at 18 months

effective at reducing or completely eliminating *E. faecalis* from the root canal space and dentinal tubules.^[17] Also, AH Plus epoxy-resin-based sealer was used as it exhibits good antibacterial effects against *E. faecalis*.^[18]

Management of the periodontal defect involved the use of PDT, which is based on the concept that an agent (photosensitizer), usually a phenothiazine compound, which absorbs light, can be preferentially taken up by bacteria, and subsequently activated by light of appropriate wavelength, in the presence of oxygen, to generate singlet oxygen and free radicals that are cytotoxic to microorganisms. Phenothiazines (e.g., toluidine blue-O and methylene blue), which bear a positive charge, can directly target both Gram-negative and Gram-positive bacteria. The positive charge promotes the binding of photosensitizer to the outer bacterial membrane, inducing localized damage, which favors its penetration.^[19]

Though we could have opted for the standard procedure of only non-surgical endodontic retreatment in treating this case, PDT was used as an adjunct in disinfecting the inaccessible furcation area and was aimed for accelerated periodontal healing in a very conservative and least invasive way.

CONCLUSION

The present case illustrates the scope of non-surgical retreatment procedure and states how the challenge posed by a failed root canal case can be successfully managed by the combination of adequate instrumentation, appropriate use of irrigants, medicaments, sealer, and the adjuvant use of recently developed technology such as PDT.

REFERENCES

1. Ingle JJ, Bakland LK. Endodontics. 4th ed. Philadelphia: Lea and Febiger; 1994. p. 32-3.
2. Del Fabbro M, Taschieri S, Testori T, Francetti L, Weinstein RL. Surgical versus non-surgical endodontic re-treatment for

- periradicular lesions. Cochrane Database Syst Rev 2007;18:CD005511.
3. Bhaskar SN. Oral surgery—oral pathology conference No. 17, Walter Reed Army Medical Center. Periapical lesions—types, incidence, and clinical features. Oral Surg Oral Med Oral Pathol 1966;21:657-71.
4. Nair PN, Sjogren U, Figdor D, Sundqvist G. Persistent periapical radiolucencies of root-filled human teeth, failed endodontic treatments, and periapical scars. Oral Surg Oral Med Oral Pathol Oral Radiol Endod 1999;87:617-27.
5. Soares J, Santos S, Silveira F, Nunes E. Nonsurgical treatment of extensive cyst-like periapical lesion of endodontic origin. Int Endod J 2006;39:566-75.
6. Catanzaro-Guimara SA, Alle N. Observations on the structure and pathogenesis of apical periodontal cyst (author's transl). Estomatol Cult 1973;7:196-201.
7. Tronstad L, Andreassen JO, Hasselgren G, Kristerson L, Riis I. pH changes in dental tissues after root canal filling with calcium hydroxide. J Endod 1981;7:17-21.
8. Longman LP, Martin MV. The use of antibiotics in the prevention of post-operative infection: A re-appraisal. Br Dent J 1991;170:257-62.
9. Komerick N, Wilson M, Poole S. The effect of photodynamic action on two virulence factors of gram-negative bacteria. Photochem Photobiol 2000;72:676-80.
10. Wainwright M, Crossley KB. Photosensitising agents-circumventing resistance and breaking down biofilms: A review. Int Biodeterior Biodegradation 2004;53:119-26.
11. Loebel NG, Andersen R, Li Y. Meta-analysis of three chronic periodontitis trials with Periowave photodisinfection. Presented at: AADR 37th Annual Meeting and Exhibition; March 31-April 5, 2008; Dallas, TX. Abstract 1222.
12. Ng YL, Mann V, Rahbaran S, Lewsey J, Gulabivala K. Outcome of primary root canal treatment: Systematic review of the literature-part 2: Influence of clinical factors. Int Endod J 2007;41:6-31.
13. Evans M, Davies JK, Sundqvist G, Figdor D. Mechanisms involved in the resistance of *Enterococcus faecalis* to calcium hydroxide. Int Endod J 2002;35:221-8.
14. Siqueira JF Jr, Sen BH. Fungi in endodontic infections. Oral Surg Oral Med Oral Pathol Oral Radiol Endod 2004;97:632-41.
15. Torabinejad M, Corr R, Handysides R, Shabahang S. Outcomes of nonsurgical retreatment and endodontic surgery: A systematic review. J Endod 2009;35:930-7.
16. Ayhan H, Sultan N, Cirak M, Ruhi MZ, Bodur H. Antimicrobial effects of various endodontic irrigants on selected microorganisms. Int Endod J 1999;32:99-102.

17. Stuart CH, Schwartz SA, Beeson TJ, Owatz CB. Enterococcus faecalis: Its role in root canal treatment failure and current concepts in retreatment. *J Endod* 2006;32:93-8.
18. Cobankara FK, Altinoz HC, Ergani O, Kav K, Belli S. *In vitro* antibacterial activities of root-canal sealers by using two different methods. *J Endod* 2004;30:57-60.
19. Soukos NS, Goodson JM. Photodynamic therapy in the control of

oral biofilms. *Periodontology* 2000 2011;55:143-66.

Cite this article as: Pruthi PJ, Yadav N, Talwar S, Lamba AK, Verma M. Adjunctive role of photodynamic therapy in the nonsurgical endodontic retreatment of a molar with grade II furcation involvement. *J Int Clin Dent Res Organ* 2014;6:50-4.

Source of Support: Nil. **Conflict of Interest:** Nil.

