

Antimicrobial Photodynamic Therapy in the Non-Surgical Treatment of Aggressive Periodontitis: A Preliminary Randomized Controlled Clinical Study

Rafael R. de Oliveira,* Humberto O. Schwartz-Filho,* Arthur B. Novaes Jr.,* and Mário Taba Jr.*

Background: The treatment of aggressive periodontitis has always presented a challenge for clinicians, but there are no established protocols and guidelines for the efficient control of the disease.

Methods: Ten patients with a clinical diagnosis of aggressive periodontitis were treated in a split-mouth design study to either photodynamic therapy (PDT) using a laser source with a wavelength of 690 nm associated with a phenothiazine photosensitizer or scaling and root planing (SRP) with hand instruments. Clinical assessment of plaque index (PI), gingival index (GI), bleeding on probing (BOP), probing depth (PD), gingival recession (GR), and relative clinical attachment level (RCAL) were made at baseline and 3 months after treatment with an automated periodontal probe.

Results: Initially, the PI was 1.0 ± 0.5 in both groups. At the 3-month evaluation, the plaque scores were reduced and remained low throughout the study. A significant reduction of GI and BOP occurred in both groups after 3 months ($P < 0.05$). The mean PD decreased in the PDT group from 4.92 ± 1.61 mm at baseline to 3.49 ± 0.98 mm after 3 months ($P < 0.05$) and in SRP group from 4.92 ± 1.14 mm at baseline to 3.98 ± 1.76 mm after 3 months ($P < 0.05$). The mean RCAL decreased in the PDT group from 9.93 ± 2.10 mm at baseline to 8.74 ± 2.12 mm after 3 months ($P < 0.05$), and in the SRP group, from 10.53 ± 2.30 mm at baseline to 9.01 ± 3.05 mm after 3 months.

Conclusion: PDT and SRP showed similar clinical results in the non-surgical treatment of aggressive periodontitis. *J Periodontol* 2007;78:965-973.

KEY WORDS

Clinical trials; periodontal diseases/therapy; photochemotherapy, photosensitizing agents.

The treatment of aggressive periodontitis has always presented a challenge for clinicians, but there are no established protocols and guidelines for the efficient control of the disease.¹ It is well known that certain periodontopathogenic bacterial species are responsible for periodontal breakdown, and the prevention of periodontitis is based on suppression or elimination of periodontopathogenic bacteria.²⁻⁴ Apart from the conventional mechanical non-surgical and surgical treatment methods, various adjunctive anti-infectious therapeutic possibilities are available. These include the use of disinfectants and various antibiotics.⁵⁻⁹ However, the application of local or systemic antibiotics is not entirely free from side effects, which can include gastrointestinal disorders, and patient compliance can be problematic.¹⁰

It is generally accepted that mechanical removal of contaminants and the adjunctive use of antibiotics and disinfectants make up the conventional treatment for aggressive periodontitis. Furthermore, the clinician is informed that the biofilm structure of the dental plaque confers remarkable resistance to species within the biofilm.¹¹⁻¹³ Also, there is an increased concern regarding the development of antibiotic resistance.¹⁰

The uncertainty about antibiotic use arises largely in part because of the lack of knowledge about microbial changes

* Department of Bucco-Maxillo-Facial Surgery and Traumatology and Periodontology, School of Dentistry of Ribeirão Preto, University of São Paulo, Ribeirão Preto, SP, Brazil.

brought about within dental biofilms. Before the notion of biofilm-conferred antibiotic resistance, one might surmise that a systemically administered antibiotic reaching the subgingival microbiota would lay waste to virtually all sensitive species in that region.¹³ After the concept of increased resistance caused by biofilm structure, one might entertain the possibility that few, if any, species are affected.^{1,13} In addition, because of variability in design of the existing studies, we are currently not able to conclude which antimicrobial agent, dose, and duration provide the optimal clinical and microbiologic effect in this group of patients.

For these reasons, alternatives that might offer the possibility of efficient removal of periodontal bacteria from the hard tissue surfaces are being sought. Photodynamic therapy (PDT) could become a new method of antibacterial treatment and may be used as adjunct to or as conventional therapy for the treatment of aggressive periodontitis.

PDT is based on the principle that a photoactivatable substance, the photosensitizer, binds to the target cell and can be activated by light of a suitable wavelength. During this process, free radicals of singlet oxygen are formed, which produce an effect that is toxic to the cell. When first reports emerged on light-absorbing properties and fluorescence of various dyes, it became clear that dye excitation by light exerts destructive action in biologic systems. This so-called “photodynamic action” was described as a process in which light, after being absorbed by dyes, sensitizes organisms for visible light-inducing cell damage.¹⁴ Raab¹⁵ studied this reaction, showing the killing of protozoa in the presence of acridine when irradiated with light in the visible range of the spectrum. Although PDT is more widely known for its application in the treatments of neoplasms,¹⁶ there is also an interest in antimicrobial photodynamic therapy because a large number of microorganisms (including oral species) have been reported to be killed in vitro by this approach.¹⁷⁻²⁰ Furthermore, the potential of some key virulence factors (lipopolysaccharide and proteases) have also been shown to be reduced by photosensitization.²¹

The bactericidal efficacy of PDT against periodontal pathogens has been shown in a study using a rat model, and the results show that toluidine blue-mediated lethal photosensitization of *Porphyromonas gingivalis* is possible in vivo and that this results in decreased bone loss.²² Sigush et al.²³ showed that PDT using a photosensitizer and a 662-nm laser light source are advantageous in reducing the periodontal signs of redness and bleeding on probing (BOP) in dogs. The procedure also seems to significantly suppress *P. gingivalis*.

The aim of this study was to investigate the applicability of photodynamic therapy in the treatment of

aggressive periodontitis through the analysis of clinical parameters.

MATERIALS AND METHODS

Patient Population

The experiment protocol was reviewed and approved by the Institution's Human Research Committee. The protocol was approved on December 7, 2005 (protocol 05.1.1038.53.9). Patients were treated sequentially following approval. Ten patients, eight women and two men, between 18 and 35 years of age (mean age, 31 years), with a clinical diagnosis of aggressive periodontitis were selected (Table 1). The selected patients had a minimum of 20 teeth (mean, 26 teeth) with at least one tooth in each posterior sextant and at least one posterior sextant with a minimum of three natural teeth. The subjects also presented with ≥ 5 mm of attachment loss around at least seven teeth involved, excluding first molars and central incisors.^{24,25} Criteria for exclusion from the study were 1) periodontal treatment within the last 6 months; 2) systemic diseases that could influence the outcome of therapy; 3) pregnancy; 4) smoking; and 5) ingestion of systemic antibiotics within the last 6 months. All participants signed informed consent forms.

Study Design

The study was performed using the split-mouth design. A total of 10 pairs of contralateral maxillary single-rooted teeth were included (10 lateral incisors, eight canines, and two premolars); each tooth of each contra-lateral pair exhibited a probing depth (PD) ≥ 5 mm on at least two aspects of the tooth. In each contralateral pair, one tooth was randomly treated, through a coin toss, with subgingival scaling and root planing (SRP) using hand instruments, whereas the other tooth was treated with PDT. All patients were treated by the same experienced operator.

Table 1.

Initial Demographic Data for the Patient Population

Parameters	
N	10
Gender	Two men and eight women
Age (years) (mean \pm SD)	31.01 \pm 4.43
N teeth (mean \pm SD)	26.7 \pm 5.14
Lateral incisors (N)	10
Canines (N)	8
Premolars (N)	2

Oral Hygiene Program

Fourteen days before treatment, all patients were enrolled in a hygiene program according to individual needs and received oral hygiene instructions. Supragingival professional tooth cleaning was performed 7 days before baseline.

Non-Surgical Treatments

The mechanical subgingival instrumentation was performed, under local anesthesia, using hand instruments (Grace curets† numbers 3/4, 5/6, 7/8, 11/12, and 13/14). For the PDT group, a diode laser‡ was selected with a wavelength of 660 nm, and a maximum power of 60 mW/cm² was used together with a phenothiazine chloride photosensitizer§ in a concentration of 10 mg/ml. The photosensitizer was applied by placing the applicator at the bottom of the periodontal pocket and was continuously deposited in a coronal direction for 1 minute followed by copious irrigation with distilled water to remove excess. In sequence, the pocket was exposed to the laser light using the fiber optic applicator¶ with a diameter of 0.6 mm for 10 seconds (Figs. 1 through 4). The treatment was done in six sites per tooth totaling 1 minute of treatment per tooth. The amount of time needed in the SRP group was, on average, 8 minutes, whereas the average time spent for the PDT group was 3 minutes. All tooth surfaces were treated either by SRP or PDT, but only proximal surfaces (mesial and distal) were considered for the clinical analysis of the evaluated parameters (total = 40 sites). To allow more comprehensive comparisons among the two groups, the sites were subset into baseline PD categories of shallow (1 to 4 mm), moderate (4 to 6 mm), and deep pockets (≥7 mm).

Clinical Measurements

At the baseline visit and after 3 months, the following clinical parameters were measured by one calibrated blinded examiner who was not involved in the treatment phase: plaque index (PI)²⁶ and gingival index (GI).²⁷ An automated periodontal probe¶ and an acrylic stent with reference marks were used to determine the exact measurement site for the following parameters: PD; gingival recession (GR); and relative clinical attachment level (RCAL), which was measured as the distance from a fixed point on the stent to the bottom of the pocket. BOP was assessed simultaneously with the pocket measurements, and the presence or absence of bleeding up to 30 seconds after probing was recorded.²⁸

Examiner Calibration

Five patients, each showing two pairs of contralateral single-rooted teeth with PDs ≥6 mm on at least one as-



Figure 1.

The photodynamic therapy was performed with a diode laser unit with 660 nm of wavelength (A); a photosensitizer (B); and a fiber optic applicator (C).

pect of each tooth, were used to calibrate the examiner. The examiner evaluated the patients on two separate occasions 48 hours apart. Calibration was accepted if measurements at baseline and after 48 hours were similar to the millimeter at ≥90% level.

Statistical Analysis

Mean values and SD were calculated. The Mann-Whitney U test was performed to determine whether the two groups had similar clinical measurements at baseline and whether one treatment produced better clinical results after a 3-month follow-up. The Wilcoxon signed-rank test was used to analyze whether clinical measurements differed before and after treatment. For all statistical analysis, a significance level of 5% was used. A software package was used for all calculations.[#]

RESULTS

The postoperative healing was uneventful in all cases. No complications such as abscesses or infections were observed throughout the study. Initially, the PI was 1.0 ± 0.6 in both groups. At 3 months, plaque scores were markedly reduced, and no statistically significant differences were observed between plaque scores of surfaces treated by both therapies (Table 2). The GI was significantly reduced in both groups at the 3-month follow-up evaluation compared to baseline ($P < 0.05$), with no statistically significant differences. At the baseline examination, 57% of the surfaces in the PDT group and 60% of the surfaces in the SRP group

† Hu-Friedy, Chicago, IL.

‡ Helbo Therapielaser, Helbo Photodynamic Systems, Grieskirchen, Austria.

§ Helbo Blue, Helbo Photodynamic Systems.

¶ Helbo 3D Pocket Probe, Helbo Photodynamic Systems.

¶ Florida Probe, Florida Probe, Gainesville, FL.

SPSS, SPSS, Chicago, IL.

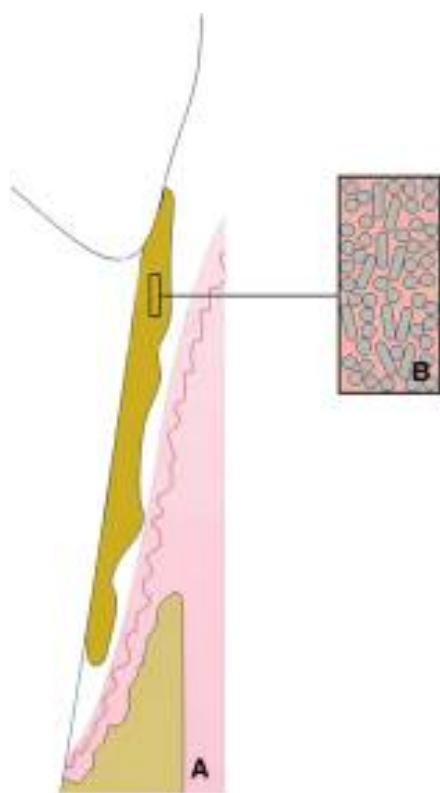


Figure 2.

A) Schematic representation showing a periodontal pocket and the subgingival biofilm. **B)** Magnification of the subgingival biofilm.

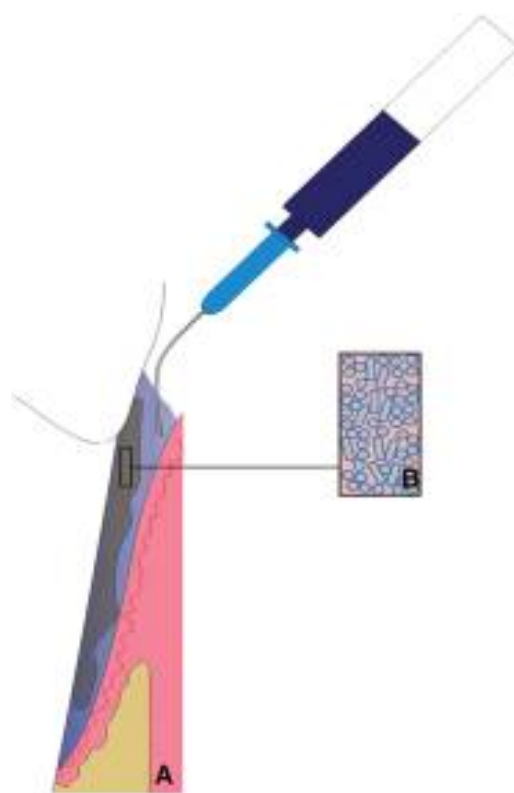


Figure 3.

A) Schematic representation showing the application of the photosensitizer. **B)** This procedure leads to staining the microorganisms in the subgingival biofilm.

showed BOP. On treatment, a marked improvement of the bleeding scores took place so that 19% of the PDT group and 21% of the SRP group had positive scores ($P < 0.05$). The mean PD, GR, and RCAL values for baseline and the 3-month evaluation for both groups are presented in Table 3. Throughout the study, a significant reduction of the PD and a significant gain of RCAL took place in both groups ($P < 0.05$; Table 3). Although at 3 months the PD reduction was more pronounced in the PDT group than the SRP group (Table 3), the difference was not statistically significant. When PD was divided into subgroups of shallow, moderate, and deep pockets, initially moderate (4 to 6 mm) and shallow pockets (1 to 4 mm) showed the greatest changes in PD (Figs. 5 and 6).

DISCUSSION

In the present clinical study, we tested the applicability of photodynamic therapy as an alternative for the treatment of aggressive periodontitis. Antibiotics were not used in this protocol; therefore, the adjunctive effect would not interfere with the results of the PDT or SRP groups. The results showed that non-surgical periodontal treatment with either PDT or SRP using hand instruments may lead to clinically and

statistically significant improvements in PD and RCAL 3 months after treatment. There were no statistically significant differences in any of the evaluated parameters between the groups. Also, the observation that the postoperative healing was uneventful in all cases throughout the study period indicates that non-surgical periodontal treatment with PDT is well tolerated.

It has been clearly shown that periodontitis is an infectious disease,^{29,30} and a current concept for treating periodontitis is primarily found on eliminating the infection. Although several studies³¹⁻³³ consider the mechanical therapy of the root surface as the basic prerequisite for a long-term treatment success, nothing can be found in the pertinent literature defining a sufficiently planed root surface from the clinical point of view. Flemmig et al.³⁴ showed that SRP alone, without additional and separately applied root planing, and despite administering systemic antibiotics, does not result in satisfactory clinical and microbiologic outcomes. More recently, Sigush et al.⁸ showed that, in generalized aggressive periodontitis, systemically administered antibiotics alone, even if preceded by the complete removal of supra- and subgingival



Figure 4.

A) Schematic representation showing the exposure of the stained bacteria to the laser beam through the fiber optic applicator. **B)** The stained bacteria are destroyed by the laser beam.

Table 2.

PI, GI, and BOP: Mean Scores (± SD; N = 10 patients) at Baseline and 3 Months

Index/Treatment	Baseline (± SD)	3 Months (± SD)	P
PI			
PDT	1.00 ± 0.50	0.7 ± 0.4	NS
SRP	1.00 ± 0.50	0.6 ± 0.4	NS
P value	NS	NS	
GI			
PDT	1.80 ± 0.60	0.60 ± 0.40	*
SRP	1.90 ± 0.70	0.60 ± 0.50	*
P value	NS	NS	
BOP			
PDT	57%	19%	*
SRP	60%	21%	*
P value	NS	NS	

Significance of differences within (Wilcoxon signed-rank test; non-parametric test) and between (Mann-Whitney U test; non-parametric test) the groups (*P < 0.05). NS = not significant.

contaminants including root planing, does not lead to good long-term results with regard to PD reduction, CAL gain, and bacterial eradication unless reinstrumentation of the affected roots is performed in an additional step.

Also, manual SRP can often be difficult and time-consuming because of the complex and unfavorable root morphology when working blindly at deep pocket

Table 3.

PD, GR, and RCAL: Mean Scores (± SD; N = 10 patients) at Baseline and 3 Months

Index/Treatment	Baseline (± SD)	3 Months (± SD)	P
PD			
PDT	4.92 ± 1.61	3.49 ± 0.98	*
SRP	4.92 ± 1.14	3.98 ± 1.76	*
P value	NS	NS	
GR			
PDT	1.03 ± 0.35	0.90 ± 0.31	NS
SRP	1.53 ± 0.56	1.50 ± 0.57	NS
P value	NS	NS	
RCAL			
PDT	9.93 ± 2.10	8.74 ± 2.12	*
SRP	10.53 ± 2.30	9.01 ± 3.05	*
P value	NS	NS	

Significance of differences within (Wilcoxon signed-rank test; non-parametric test) and between (Mann-Whitney U test; non-parametric test) the groups (*P < 0.05). NS = not significant.

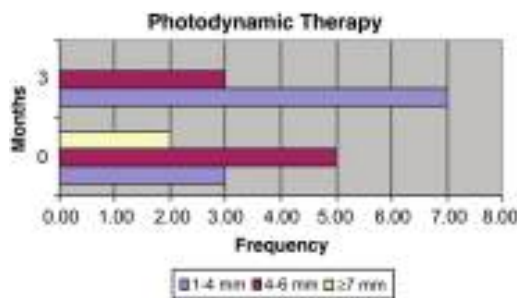


Figure 5.

Plot of frequency distribution for the PDT group of the pockets at baseline and 3 months at sites with initial PDs of 1 to 4 (shallow pockets), 4 to 6 (moderate pockets), and ≥7 mm (deep pockets; N = 10 patients).

sites.³⁵ Because periodontal debridement requires a certain level of skill, time, and endurance, it seems appropriate to choose an easily handled apparatus that allows one to achieve a highly efficient and time-saving removal of contaminants, with less effort on behalf of the clinician.

The effect of SRP on the subgingival microflora has been studied in several studies as described in recent reviews.^{36,37} There is general agreement that this procedure, in addition to improving clinical parameters, reduces the microbial load and results in a shift toward a more health-compatible microflora.^{38,39} However, there are conflicting reports about the ability of SRP to completely eradicate or suppress important periodontal pathogens. *Tannerella forsythensis* and

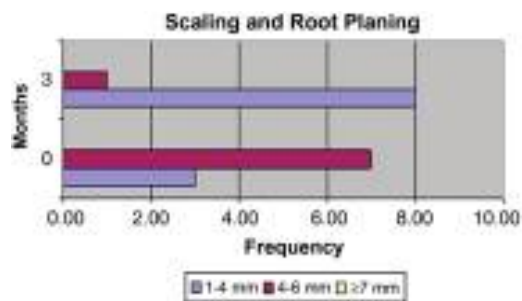


Figure 6.

Plot of frequency distribution for the SRP group of the pockets at baseline and 3 months at sites with initial PDs of 1 to 4 (shallow pockets), 4 to 6 (moderate pockets), and ≥ 7 mm (deep pockets; $N = 10$ patients).

especially *Actinobacillus actinomycetemcomitans* have been shown to remain in periodontal pockets after non-surgical therapy.^{40,41} Bacterial recolonization or regrowth in the subgingival environment is anticipated after SRP, even shortly after treatment. It is suggested that to prevent a return to pretreatment levels of pathogens, regularly performed supportive periodontal therapy is essential.³⁶ This may also be the case with the use of PDT.

To supplement the armament of antibacterial measures, in recent years different attempts have been made to introduce antibacterial photodynamic therapy as an additional possibility for efficient control of the disease. Various *in vitro* studies⁴²⁻⁴⁵ have shown that periodontal microorganisms can be effectively suppressed with PDT. Whether PDT can be clinically implemented as a successful anti-infectious procedure in periodontal diseases is not clear because of the lack of controlled clinical studies. On the mineralized surface of the tooth, the periodontopathogenic species form a complex bacterial biofilm,⁴⁶ which can apparently penetrate the soft tissue.⁴⁷ The biofilm is difficult to eliminate using the conventional periodontal treatment modalities that are available. Meanwhile, the bactericidal efficacy of PDT against periodontal bacteria has been shown using both rat and dog models.^{22,23,48} Furthermore, histologic examination of the periodontal tissues of the rats after PDT showed no adverse effects, in that no ulcer formation on the epithelium or inflammation in the connective tissue was detected, even with the highest light doses and toluidine blue concentrations used.²²

The subjects in this study presented a mean PD of 6.58 ± 1.21 mm at the initial examination. At baseline, after distribution of the groups, the PDT group showed a mean PD of 4.92 ± 1.61 mm and the SRP group showed a mean PD of 4.92 ± 1.14 mm. It is important to emphasize that the patients received oral hygiene instructions according to individual needs and a

supragingival professional tooth cleaning 7 days before baseline; this may explain the PD reduction that occurred. At 3-month examination, the PD for the PDT group was 3.49 ± 0.98 , and for the SRP group it was 3.98 ± 1.76 mm. The results were statistically significant when comparing the baseline with the 3-month evaluation for both groups ($P < 0.05$). The comparison between groups showed no statistically significant differences in all evaluated parameters after 3 months; however, numerically, the results were more pronounced for the PDT group in PD, GR, and RCAL. All other studied parameters such as PI, GI, and BOP showed marked improvements between baseline and the 3-month reevaluation, but when both groups were compared, the differences were not statistically significant.

Clinical studies have shown that reduction of PD and enhancement of the CAL after both surgical and non-surgical periodontal treatment is dependent on the initial PD (i.e., the greater the initial PD and CAL, the greater PD reduction and CAL gain).^{35,49,50} Furthermore, it should be pointed out that, in the present study, both treatments were equivalent in reducing moderate and shallow pockets. Figure 5 shows the pocket frequency distribution for the PDT group regarding shallow, moderate, and deep pockets. This group presented two pockets with PD of ≥ 7 mm, five with PD between 4 and 6 mm, and three between 1 and 4 mm at baseline. At the 3-month evaluation, the PDT group presented an increase in the number of shallow pockets from three to seven; for the moderate pockets, there was a reduction in the number of pockets from five to three. Pockets with PD of ≥ 7 mm were no longer found, which may indicate the ability of photodynamic therapy in dealing with deep probing sites. The SRP group (Fig. 6) presented seven pockets at baseline with a PD between 4 and 6 mm and three pockets between 1 and 4 mm. At the 3-month evaluation, this group also showed an increase in the number of shallow pockets from three to eight; for the moderate pockets, the reduction was from seven to one. In this group, pockets of ≥ 7 mm were not found, which was different from what occurred for the PDT group. The clinical changes in the SRP group were comparable to those reported in a number of clinical trials that described the effectiveness of non-surgical periodontal treatment.^{35,49,51,52} The reduction of gingival recession in the PDT group may be attributed to the atraumatic use of the optic fibers.

The standard treatment for aggressive periodontitis remains highly non-specific, consisting mostly of the mechanical debridement of the affected root surfaces in conjunction with antibiotics. However, a small, although relevant, proportion of sites and patients do not respond adequately to this therapy.⁵³ Antimicrobial chemotherapy may further suppress the periodontal

pathogens and increase the benefits obtained by conventional mechanical treatment. Numerous systemic and local antimicrobial chemotherapeutic agents have been evaluated for the treatment of periodontitis with various degrees of success.⁵⁴⁻⁵⁷ A lack of effectiveness of some of the antibiotics used may be caused by development of drug-resistant strains.^{58,59} On the other hand, because of its localized and non-invasive nature, the side effects associated with many antibiotics (e.g., gastrointestinal disturbance) are unlikely to occur with PDT. Furthermore, development of resistance to PDT would seem to be unlikely because its bactericidal activity is caused by singlet oxygen and other reactive species such as hydroxyl radicals, which affect a range of cellular targets.^{60,61}

PDT requires two components: a light source and a photosensitizer capable of binding to the targeted cell. The photosensitization may be important in dealing with aggressive periodontitis because the photosensitizer is capable of penetrating through the epithelium and connective tissue,²² as are the periodontopathogens, especially *A. actinomycetemcomitans*, which can infiltrate through the epithelial barrier into the periodontal tissues. Considering that PDT is not truly a mechanical therapy, residual calculus is expected to occur. Because of the lower presence of calculus, aggressive forms of disease and maintenance patients are more likely to benefit from the antimicrobial effect. PDT has advantages such as reducing the treatment time, no need for anesthesia, destruction of bacteria in a very short period of time (<60 seconds), unlikely development of resistance by the target bacteria, and avoidable damage to the adjacent host tissues.²²

PDT and SRP showed similar clinical outcomes in the non-surgical treatment of aggressive periodontitis. Further studies using larger sample sizes are warranted to confirm these results.

ACKNOWLEDGMENT

This study was partially supported by Helbo Photodynamic Systems, Grieskirchen, Austria.

REFERENCES

- Carvalho LH, D'Avila GB, Leão A, Haffajee AD, Socransky SS, Feres M. Scaling and root planing, systemic metronidazole and professional plaque removal in the treatment of chronic periodontitis in a Brazilian population: I. Clinical results. *J Clin Periodontol* 2004; 31:1070-1076.
- Tanner ACR, Socransky SS, Goodson JM. Microbiota of periodontal pockets losing crestal alveolar bone. *J Periodontol Res* 1984;19:279-291.
- Iino Y, Hopes RM. The bone resorbing activities in tissue culture of lipopolysaccharides from the bacteria *Actinobacillus actinomycetemcomitans*, *Bacteroides gingivallis* and *Capnocythofaga ochracea* isolated from human mouths. *Arch Oral Biol* 1984;29:59-63.
- Boom-van Noorloos AA, van der Meer JWM, van de Gevel JS, Schepens E, van Steenberghe TJM, Burger EH. *Bacteroides gingivallis* stimulates bone resorption via interleukin-1 production by mononuclear cells. *J Clin Periodontol* 1990;17:409-413.
- Bollen CM, Quirynen M. Microbiological response to mechanical treatment in combination with adjunctive therapy. A review of the literature. *J Periodontol* 1996; 67:1143-1158.
- Greenstein G. Non-surgical periodontal therapy in 2000. A literature review. *J Am Dent Assoc* 2000;131: 1580-1592.
- Loesche WJ, Grossman NS. Periodontal disease as a specific, albeit chronic, infection: Diagnosis and treatment. *Clin Microbiol Rev* 2001;14:727-752.
- Sigusch B, Beier M, Klinger G, Pfister W, Glockmann E. A 2-step non-surgical procedure and systemic antibiotics in the treatment of rapidly progressive periodontitis. *J Periodontol* 2001;72:275-283.
- Slots J. Selection of antimicrobial agents in periodontal therapy. *J Periodontol Res* 2002;37:389-398.
- Pallasch TJ. Antibiotic resistance. *Dent Clin North Am* 2003;47:623-639.
- Nichols WW, Evans MJ, Slack MPE, Walmsley HL. The penetration of antibiotics into aggregates of mucoid and non-mucoid *Pseudomonas aeruginosa*. *J Gen Microbiol* 1989;135:1291-1303.
- Hoyle BD, Jass J, Costerton JW. The biofilm glycocalyx as a resistance factor. *J Antimicrob Chemother* 1990;26:1-6.
- Feres M, Haffajee AD, Allard K, Som S, Socransky SS. Change in subgingival microbial profiles in adult periodontitis subjects receiving either systemically-administered amoxicillin or metronidazole. *J Clin Periodontol* 2001;28:597-609.
- Marcacci A, Sur L. Action of the alkaloids in the vegetable and animal kingdoms (in Italian). *Arch Ital Biol* 1888;9:2-4.
- Raab O. The effect of fluorescent agents on infusoria (in German). *Z Biol* 1900;39:524-526.
- Dougherty TJ, Marcus SL. Photodynamic therapy. *Eur J Cancer* 1992;28A:1734-1742.
- Martinetto P, Gariglio M, Lombard GF, Fiscella B, Boggio F. Bactericidal effects induced by laser irradiation and haematoporphyrin against Gram-positive and Gram-negative microorganisms. *Drugs Exp Clin Res* 1986;12:335-342.
- Wilson M. Photolysis of oral bacteria and its potential use in the treatment of caries and periodontal disease. *J Appl Bacteriol* 1993;75:299-306.
- DeSimone NA, Christiansen C, Dore D. Bactericidal effect of 0.95-mW helium-neon and a 5-mW indium-gallium-aluminum-phosphate laser irradiation at exposure times of 30, 60, and 120 seconds on photosensitized *Staphylococcus aureus* and *Pseudomonas aeruginosa* in vitro. *Phys Ther* 1999;79:839-846.
- Wilson M, Dobson J, Harvey W. Sensitization of oral bacteria to killing by low-power laser radiation. *Curr Microbiol* 1992;25:77-81.
- Kömerik N, Wilson M, Poole S. The effect of photodynamic action on two virulence factors of Gram-negative bacteria. *Photochem Photobiol* 2000;72:676-680.
- Kömerik N, Nakanishi H, Mac Robert AJ, Henderson B, Speight P, Wilson M. In vivo killing of *Porphyromonas gingivallis* by toluidine blue-mediated photosensitization in an animal model. *Antimicrob Agents Chemother* 2003;47:932-940.

23. Sigusch BW, Pfitzner A, Albrecht V, Glockmann E. Efficacy of photodynamic therapy on inflammatory signs and two selected periodontopathogenic species in a beagle dog model. *J Periodontol* 2005;76:1100-1115.
24. American Academy of Periodontology. Diagnosis of periodontal diseases (position paper). *J Periodontol* 2003;74:1237-1247.
25. Pawlowski AP, Chen A, Hacker BM, Mancl LA, Page RC, Roberts FA. Clinical effects of scaling and root planing on untreated teeth. *J Clin Periodontol* 2005;32:21-28.
26. Silness J, Loe H. Periodontal disease in pregnancy. II. Correlation between oral hygiene and periodontal condition. *Acta Odontol Scand* 1964;22:112-135.
27. Loe H, Silness J. Periodontal disease in pregnancy. I. Prevalence and severity. *Acta Odontol Scand* 1963;21:533-551.
28. Schwarz F, Berakdar M, Georg T, Reich E, Sculean A. Clinical evaluation of an Er:YAG laser combined with scaling and root planing for non-surgical periodontal treatment. A controlled, prospective clinical study. *J Clin Periodontol* 2003;30:26-34.
29. Haffajee AD, Socransky SS. Microbial etiological agents of destructive periodontal diseases. *Periodontol* 2000 1994;5:78-111.
30. Slots J, Genco RJ. Black-pigmented *Bacteroides* species, *Capnocytophaga* species, and *Actinobacillus actinomycetemcomitans* in human periodontal disease: Virulence factors in colonization, survival, and tissue destruction. *J Dent Res* 1984;63:412-421.
31. Greenstein G. Periodontal response to mechanical non-surgical therapy: A review. *J Periodontol* 1992;63:118-130.
32. Moore J, Wilson M, Kieser JB. The distribution of bacterial lipopolysaccharide (endotoxin) in relation to periodontally involved root surfaces. *J Clin Periodontol* 1986;13:748-751.
33. Badersten A, Nilvéus R, Egelberg J. 4-year observations of basic periodontal therapy. *J Clin Periodontol* 1987;14:438-444.
34. Flemmig TF, Milián E, Karch H, Klaiber B. Differential clinical treatment outcome after systemic metronidazole and amoxicillin in patients harboring *Actinobacillus actinomycetemcomitans* and/or *Porphyromonas gingivalis*. *J Clin Periodontol* 1998;25:380-387.
35. Ramfjord SP, Caffesse RG, Morrison EC, et al. Four modalities of periodontal treatment compared over 5 years. *J Clin Periodontol* 1987;14:445-452.
36. Petersilka GJ, Ehmke B, Flemmig TF. Antimicrobial effects of mechanical debridement. *Periodontol* 2000 2002;28:56-71.
37. Umeda M, Takeuchi Y, Noguchi K, Huang Y, Koshy G, Ishikawa I. Effects of non-surgical periodontal therapy on the microbiota. *Periodontol* 2000 2004;36:98-120.
38. Mousques T, Listgarten M, Phillips R. Effect of scaling and root planing on the composition of the human subgingival microbial flora. *J Periodontol Res* 1980;15:144-151.
39. Haffajee AD, Cugini MA, Dibart S, Smith C, Kent RL, Socransky SS. The effect of SRP on the clinical and microbiological parameters of periodontal diseases. *J Clin Periodontol* 1997;24:324-334.
40. Renvert S, Wikstrom M, Dahlen G, Slots J, Egelberg J. Effect of root debridement on the elimination of *Actinobacillus actinomycetemcomitans* and *Bacteroides gingivalis* from periodontal pockets. *J Clin Periodontol* 1990;17:345-350.
41. Takamatsu N, Yano K, He T, Umeda M, Ishikawa I. Effect of initial periodontal therapy on the frequency of detecting *Bacteroides forsythus*, *Porphyromonas gingivalis* and *Actinobacillus actinomycetemcomitans*. *J Periodontol* 1999;70:574-580.
42. Sarkar S, Wilson M. Lethal photosensitization of bacteria in subgingival plaque from patients with chronic periodontitis. *J Periodontol Res* 1993;28:204-210.
43. Soukos NS, Ximenez-Fyvie LA, Hamblin MR, Socransky SS, Hasan T. Targeted antimicrobial photochemotherapy. *Antimicrob Agents Chemother* 1998;42:2595-2601.
44. Pfitzner A, Sigusch BW, Albrecht V, Glockmann E. Killing of periodontopathogenic bacteria by photodynamic therapy. *J Periodontol* 2004;75:1343-1349.
45. Wilson M, Dobson J, Harvey W. Sensitization of oral bacteria to killing by low-power laser radiation. *Curr Microbiol* 1992;25:77-81.
46. Kolenbrander PE. Oral microbial communities: Biofilms, interactions, and genetic systems. *Annu Rev Microbiol* 2000;54:413-437.
47. Page RC, Offenbacher S, Schroeder HE, Seymour GJ, Kornman KS. Advances in the pathogenesis of periodontitis: Summary of developments, clinical implications and future directions. *Periodontol* 2000 1997;14:216-248.
48. Soukos NS, Mulholland SE, Socransky SS, Doukas AG. Photodestruction of human dental plaque bacteria: Enhancement of the photodynamic effect by photomechanical waves in an oral biofilm model. *Lasers Surg Med* 2003;33:161-168.
49. Kaldahl WB, Kalkwarf KL, Patil KD, Molvar MP, Dyer JK. Long-term evaluation of periodontal therapy: I. Response to 4 therapeutic modalities. *J Periodontol* 1996;67:93-102.
50. Schwarz F, Sculean A, Georg T, Reich E. Periodontal treatment with an Er:YAG laser compared to scaling and root planing. A controlled clinical study. *J Periodontol* 2001;72:361-367.
51. Badersten A, Nilveus R, Egelberg J. Effect of non-surgical periodontal therapy. I. Moderately advanced periodontitis. *J Clin Periodontol* 1981;8:57-72.
52. Badersten A, Nilveus R, Egelberg J. Effect of non-surgical periodontal therapy. II. Severely advanced periodontitis. *J Clin Periodontol* 1984;11:63-76.
53. Walker CB, Gordon JM, Magnusson I, Clark WB. A role for antibiotics in the treatment of refractory periodontitis. *J Periodontol* 1993;64(Suppl.):772-781.
54. Chaves ES, Jeffcoat MK, Ryerson CC, Snyder B. Persistent bacterial colonization of *Porphyromonas gingivalis*, *Prevotella intermedia*, and *Actinobacillus actinomycetemcomitans* in periodontitis and its association with alveolar bone loss after 6 months of therapy. *J Clin Periodontol* 2000;27:897-903.
55. Loesche WJ, Syed SA, Morrison EC, Kerry GA, Higgins T, Stoll J. Metronidazole in periodontitis. I. Clinical and bacteriological results after 15 to 30 weeks. *J Periodontol* 1984;55:325-335.
56. Renvert S, Dahlen G, Wikstrom M. Treatment of periodontal disease based on microbiological diagnosis. Relation between microbiological and clinical parameters during 5 years. *J Periodontol* 1996;67:562-571.
57. Stabholz A, Nicholas AA, Zimmerman GJ, Wikesjö UME. Clinical and antimicrobial effects of a single episode of subgingival irrigation with tetracycline HCl

- or chlorhexidine in deep periodontal pockets. *J Clin Periodontol* 1998;25:794-800.
58. Feres M, Haffajee AD, Gonçalves C, et al. Systemic doxycycline administration in the treatment of periodontal infections. II. Effect on antibiotic resistance of subgingival species. *J Clin Periodontol* 1999;26:784-792.
59. Olsvik B, Tenover FC. Tetracycline resistance in periodontal pathogens. *Clin Infect Dis* 1993;16(Suppl. 4):S310-S313.
60. Bhatti M, MacRobert A, Meghji S, Henderson B, Wilson M. A study of the uptake of toluidine blue O by *Porphyromonas gingivalis* and the mechanism of lethal photosensitisation. *Photochem Photobiol* 1998;68:370-376.
61. Ito T, Kobayashi K. In vivo evidence for the photodynamic membrane damage as a determining step of the inactivation of yeast cells sensitized by toluidine blue. *Photochem Photobiol* 1977;25:399-401.

Correspondence: Dr. Arthur Belém Novaes Jr., Faculty of Odontology of Ribeirão Preto, University of São Paulo, Av. do Café s/n, 14040-904, Ribeirão Preto, SP, Brazil. E-mail: novaesjr@forp.usp.br.

Accepted for publication January 17, 2007.